

# Current Treatment Strategies in Cutaneous Malignant Melanoma of the Head and Neck

Erdoğan ÖZGÜR<sup>1</sup>, Barış KARAKULLUKÇU<sup>2</sup>, Görkem ESKİİZMİR<sup>3</sup>

*1 Muğla Sıtkı Koçman University, Department of Otorhinolaryngology, Muğla, Turkey - ORCID ID:0000-0003-2494-4244*

*2 The Netherlands Cancer Institute, Antoni van Leeuwenhoek Hospital, Department of Head and Neck Oncology and Surgery, Amsterdam, THE NETHERLANDS - ORCID ID:0000-0002-1700-5743*

*3 Manisa Celal Bayar University, Department of Otorhinolaryngology, Manisa, TURKEY - ORCID ID:0000-0002-3125-8288*

## Abstract

Cutaneous malignant melanoma is potentially an important health problem for white people. The incidence of melanoma is rising faster than other solid cancers. Despite the new melanoma drugs surgery for localised melanoma and regional metastasis is still the standard of care. However management of cutaneous melanoma differs from other cancers at some points such as biopsy tech-

nique, surgical margins, incorporation of sentinel lymph node biopsy for staging etc. In this review we focused on the role of the head and neck surgeon in management of cutaneous melanoma of head and neck region according to current knowledge.

**Keywords:** Melanoma, head and neck neoplasms, surgery, sentinel lymph node biopsy

## Introduction

Malignant melanoma of the head and neck is relatively rare among skin cancers. However, it is an important health problem because of its morbidity and mortality. Cutaneous melanoma is responsible for up to 75% of skin cancer deaths [1]. According to the data of the World Health Organization, the incidence of cutaneous melanoma is on the rise particularly in developed and developing countries where fair-skinned people exposed to the sun [2]. The incidence rate is <10-25 new melanoma cases per 100.000 inhabitants in Europe; it is 20-30/100.000 inhabitants in the United States of America. Of note, the highest incidence is in Australia, which is 50-60/100.000 inhabitants [3]. According to the GLOBOCAN 2012 report, the estimated number of new cases expected in developed countries is about 100.000 in men and women [4].


In Turkey, approximately 2.600 new cases are detected every year [5]. Even though ultraviolet exposure is the major etiologic factor for melanoma and non-melanoma skin cancers; melanoma differs from non-melanoma skin cancers in several aspects such as tumor biology and behavior, and metastatic cascade. The typical phenotype of a melanoma patient is pale white skin, red or blond hair, and blue eyes. About 80% of patients with head and neck cutaneous melanoma are older than 80 years [6]. For head and neck cutaneous melanoma face, scalp, neck and external ear are the most common regions as have the highest potential for sun exposure. Moreover, the phenotypic characteristics and environmental factors and immunosuppression are the major risk factors for malignant melanoma particularly in transplant patients [6]. Classically, four subtypes of cutaneous melanomas can be identified histologically and clinically: superficial spread-

**Correspondence:** Erdoğan Özgür  
Muğla Sıtkı Koçman University, Department of Otorhinolaryngology, 48000, Kötekli, Muğla, TURKEY

e-mail: erduvan@hotmail.com

**Received:** October 27, 2018; **Accepted:** February 6, 2019

Online available at:  
www.entupdates.org



ing melanoma, nodular melanoma, lentigo maligna melanoma, acral lentiginous melanoma. Superficial spreading melanoma is the most frequent histopathologic subtype, composing about 59%, followed by nodular melanoma at 21%, and lentigo-maligna melanoma at 11% [7].

Moreover cutaneous malignant melanoma differs with TNM staging than the other skin cancers (Table 1) [8]. Correct staging constitutes the first step of melanoma management. The diagnosis and treatment of malignant melanoma of the head and neck require a multidisciplinary teamwork including head and neck surgeon, dermatologist, radiation oncologist, medical oncologist, radiologist and pathologist. The purpose of the current review was to comprehensively discuss the role of head neck surgeons in perspective of three subtitles: (i) the biopsy technique in malignant melanoma, (ii) surgical excision of primary tumor in malignant melanoma, and (iii) the management of lymph nodes in malignant melanoma.

## (i) Biopsy Technique in Cutaneous Malignant Melanoma

### 1. Which biopsy technique should be performed for malignant melanoma?

Early diagnosis of melanoma is a cornerstone for treatment success. Melanoma develops from precursor lesions in approximately 20-40% of cases [9]. The changing and evolving features of a nevi are characteristic signs of a melanoma. These features are abbreviated as “ABCDE” signs of melanoma (*A*symmetry, irregular *B*orders,  $\geq 1$  or uneven distribution of *C*olor, large ( $\geq 6$  mm) *D*iameter, the *E*volution of a mole) which can be detected using a dermoscope or confocal laser scanning microscopy. Therefore, use of a dermoscopy may provide a remarkable decrease in unnecessary surgeries [10].

The gold standart method for the diagnosis of a clinically suspicion lesion is complete excision with the inclusion of a surgical margin of few millimetres to allow for histopathological examination. However, an incisional or punch biopsies containing all the layers of the dermis may also be performed for suspicious lesions that are adjacent to vital structures (eyes, lips, nose, etc.) and require extensive resection. Incisional biopsies or partial biopsy methods such as curettage or punches should not be performed when an excisional biopsy is technically possible; because it may change histopathological features which are imperative for conclusion and staging. In addition, large tumor resections are not recommended for diagnosis.

### 2. What are the key features that should be evaluated in a pathology report of a patient with cutaneous malignant melanoma?

In cutaneous malignant melanoma, the assessment of a pathology report is of utmost important for accurate staging and treatment plan. Therefore, a close communication with the pathologist is crucial. A pathology report should include:

- a. Tumor thickness (Breslow)
- b. Level of invasion (Clark)
- c. Histopathologic type of melanoma
- d. Presence or absence of ulceration
- e. Mitotic index
- f. Growth phase (horizontal or vertical)
- g. Vascular or perineural involvement
- h. Lateral and deep surgical margins

Moreover, molecular analysis and mutation tests (BRAF, NRAS or *c-kit* mutations) may be required particularly for patients with distant metastasis or non-resectable regional metastasis, who are candidates of systemic or targeted medical treatment [11]. After the histopathological diagnosis of malignant melanoma, a detailed physical examination for other suspicious pigmented lesions, tumor satellites, regional lymph node and systemic metastases should be performed.

### 3. What are the required imaging steps after confirming melanoma?

Routine imaging is not recommended for Stage 0, IA, IB, II melanoma. However, cervical nodal ultrasound imaging should be performed if sentinel lymph node (SLN) biopsy is planned (stage I and II). The next step should be a fine needle or tru-cut biopsy if a suspicious lymph node is detected via ultrasound. Fine-needle aspiration biopsy has been demonstrated to have high sensitivity and specificity for detecting lymph node involvement [12]. If a lymph node involvement is detected (stage III), an imaging technique is a prerequisite for the evaluation of distant metastasis. The recommended imaging modalities include contrast enhanced thorax/abdomen/pelvic computerized tomography or whole body positron emission tomography/computerized tomography scan with or without contrast enhanced brain magnetic resonance imaging. It is noteworthy that contrast enhanced neck computerized tomography is generally indicated for cutaneous malignant melanoma of head and neck [13, 14].

**Table 1.** Melanoma of the Skin Staging (8th Edition).

Primary tumor (T)	
TX	Primary tumor cannot be assessed (ie, curettaged melanoma)
T0	No evidence of primary tumor
Tis	Melanoma in situ
T1	Thickness $\leq 1.0$ mm
T1a:	$< 0.8$ mm without ulceration
T1b:	$< 0.8$ mm with ulceration, or 0.8-1.0 mm with or without ulceration
T2	Thickness $> 1.0$ -2.0 mm
T2a:	Without ulceration
T2b:	With ulceration
T3	Thickness $> 2.0$ -4.0 mm
T3a:	Without ulceration
T3b:	With ulceration
T4	Thickness $> 4.0$ mm
T4a:	Without ulceration
T4b:	With ulceration
Regional lymph nodes (N)	
NX	Regional nodes cannot be assessed (ie, previously removed for another reason)
N0	No regional metastases detected
N1	One tumor-involved lymph node or in-transit, satellite, and/or microsatellite metastases with no tumor-involved nodes
N1a:	One clinically occult (ie, detected by sentinel lymph node biopsy [SLNB]; no in-transit, satellite, or microsatellite metastases
N1b:	One clinically detected; no in-transit, satellite, or microsatellite metastases
N1c:	No regional lymph node disease; in-transit, satellite, and/or microsatellite metastases found
N2	Two or three tumor-involved nodes; or in-transit, satellite, or microsatellite metastases
N2a:	Two or three clinically occult (ie, detected by SLNB); no in-transit, satellite, or microsatellite metastases
N2b:	Two or three clinically detected; no in-transit, satellite, or microsatellite metastases
N2c:	One clinically occult or clinically detected; in-transit, satellite, and/or microsatellite metastases found
N3	$\geq 4$ tumor-involved nodes or in-transit, satellite, and/or microsatellite metastases with $\geq 2$ tumor-involved nodes or any number of matted nodes without or with in-transit, satellite, and/or microsatellite metastases
N3a:	$\geq 4$ clinically occult (ie, detected by SLNB); no in-transit, satellite, or microsatellite metastases
N3b:	$\geq 4$ , at least one of which was clinically detected, or presence of any matted nodes; no in-transit, satellite, or microsatellite metastases
N3c:	$\geq 2$ clinically occult or clinically detected and/or presence of any matted nodes, with presence of in-transit, satellite, and/or microsatellite metastases
Distant metastasis (M)	
M0	No detectable evidence of distant metastases
M1a	Metastases to skin, soft tissue (including muscle), and/or nonregional lymph nodes
M1b	Lung metastasis, with or without M1a involvement
M1c	Distant metastasis to non-central nervous system (CNS) visceral sites with or without M1a or M1b involvement
M1d	Distant metastasis to CNS, with or without M1a or M1b involvement

Clinical Staging

Stage	T	N	M
0	Tis	N0	M0
I A	T1a	N0	M0
I B	T1b	N0	M0
II A	T2a	N0	M0
	T2b	N0	M0
II B	T3a	N0	M0
	T3b	N0	M0
II C	T4a	N0	M0
	T4b	N0	M0
III	Any T, Tis	N1, N2, or N3	M0
IV	Any T	Any N	M1

Pathological Staging

Stage	T	N	M
0	Tis	N0	M0
I A	T1a, T1b	N0	M0
IB	T2a	N0	M0
II A	T2b, T3a	N0	M0
II B	T3b, T4a	N0	M0
II C	T4b	N0	M0
III A	T1a/b, Ta	N1a, N2a	M0
III B	T0	N1b, N1c	M0
	T1a/b	N1b/c, N2b	M0
	T2b, T3a	N1a/b/c, N2 a/b	M0
III C	T0	N2b/c, N3b/c	M0
	T1a/b, T2a/b, T3a	N2c, N3a/b/c	M0
	T3b, T4a	Any N ≥N1	M0
	T4b	N1a/b/c, N2a/b/c	M0
III D	T4b	N3a/b/c	M0
IV	Any T	Any N	M1

## (ii) Surgical Excision of Primary Tumor in Malignant Melanoma

### 1. What is the surgical margin for cutaneous malignant melanoma of the head and neck?

Definitive surgical excision should be performed with safety margins preferentially within 4-6 weeks of initial diagnosis. In malignant melanoma, total excision of the primary tumor plays an important role in reducing the risk of local recurrence and increasing the disease-free survival. According to the current recommendations based on both prospective, randomised studies and international consensus conferences, safe but narrow margins are appropriate contrary to the formerly used procedures; because no additional improvement on survival has been determined with extended and wide surgical margins (4 cm) [15-18]. Regarding to this context, the extent of surgical margin according to T-stage and tumor thickness is presented in Table 2 [American Joint Committee on Cancer (AJCC) 8th edition] [11].

**Table 2.** Surgical margins according to T-stage and tumor thickness in malignant melanoma.

T-Stage	Tumor thickness	Surgical margin (Recommendation)
Tis	In situ	0.5-1.0 cm
T1	<1.0 mm	1.0 cm
T2	1.0-2.0 mm	1-2 cm
T3	2.0-4.0 mm	2.0 cm
T4	>4.0 mm	2.0 cm

Despite the data presented in Table 2, surgical margins should be individualized according to the anatomic neighborhoods and relationships.

It is known that the presence of vital structures in the head and neck region and the difficulty of identifying tumor boundaries due to sun exposure require careful consideration of surgical margins in skin cancers. In relation to this clinical challenge, we have reported there liable role of “staged surgery” for the reduction of local recurrences in high-risk non-melanoma skin cancers [19]. Furthermore, Moyer et al. concluded that staged tumor resection was an effective and useful technique and decreased local recurrences in cutaneous malignant melanoma of the head and neck [20].

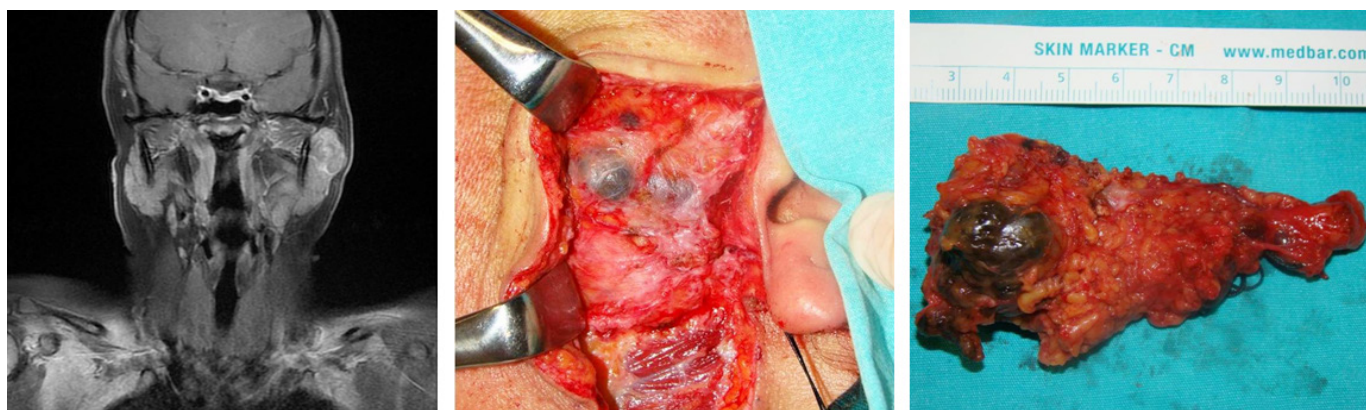
### The Management of Lymph Nodes in Cutaneous Malignant Melanoma

An additional procedure is not recommended for *in situ* or Stage Ia malignant melanoma cases [<0.8 mm, ulceration (-)]. The current approach to the lymph nodes due to clinical evaluation of cases with a tumor thickness > 0.8 mm is presented in Figure 1.

In patients with cutaneous malignant melanoma, lymph node positivity can be detected in two different clinical situations (Figure 1): (i) clinical and radiological evaluation and (ii) SLN biopsy.

### 1. What should I do when a lymph node positivity was detected in clinical and/or radiological evaluation?

According to the current staging system [8], lymph node involvement has been staged as a stage III malignant melanoma [21]. Therefore, therapeutic lymph node dissection with large tumor excision is recommended [3]. Risk of regional spread into the intraparotidial lymph nodes particularly in melanomas located on the face and auricle, should be



**Figure 1.** A case with intraparotidial lymph node metastasis of primary conjunctival melanoma.

kept in mind. In case of positive lymph nodes in the parotid gland, only superficial parotidectomy is inadequate and adding dissection of neck lymph nodes is recommended [22] (Figure 2). Moreover, Mayo Clinic suggested to perform total parotidectomy for patients with metastatic malignant melanoma and advocated that total parotidectomy might provide a better regional control when compared with superficial parotidectomy [23]. Adjuvant radiotherapy may be indicated for locoregional treatment in selected cases (high-risk cases, positive number of lymph nodes, macroscopic extranodal involvement, etc.). Agrawal et al. have a large retrospective review on the role of adjuvant RT in controlling nodal recurrence. They demonstrated that at a median 5 years follow-up regional recurrence observed in 10% of patient selected to receive adjuvant RT, compared

to 41% on who declined adjuvant RT [24]. Additionally, other current strategies for these patients are: (i) Observation, (ii) Nivolumab, (iii) Dabrafenib/ trametinib (especially for cases with BRAF V600 mutation), (iv) High dose ipilimumab, (v) Interferon alfa or (vi) Biochemotherapy. Therefore, adjuvant treatments should be individualized and discussed in multidisciplinary head and neck tumor board.

**2. Observation or SLN biopsy? When the clinical lymph node is negative?**

Sentinel lymph node biopsy is essential and strongly recommended for the complete staging of primary melanoma (Figure 3). The procedure is indicated especially for intermediate thickness melanoma (pT2/3). Nevertheless, benefits of SLN biopsy are still under debate. Recently, two

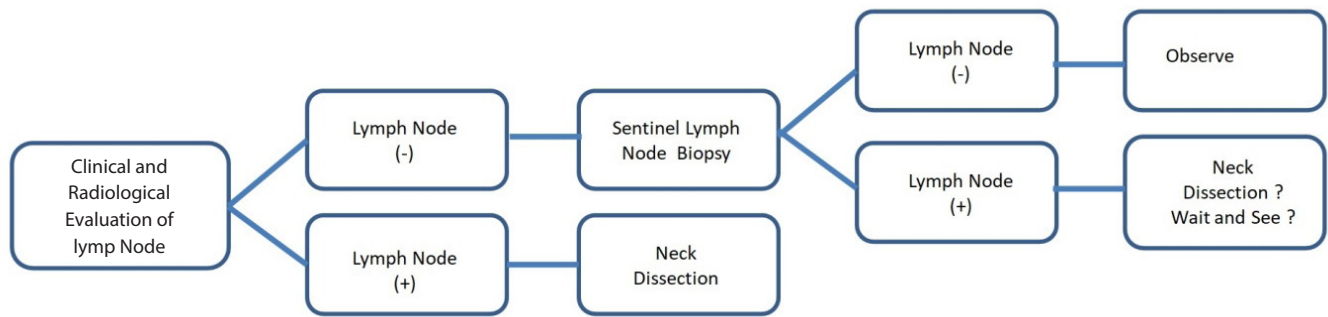


Figure 2. The clinical and radiological evaluation of lymph nodes in cutaneous malignant melanoma.

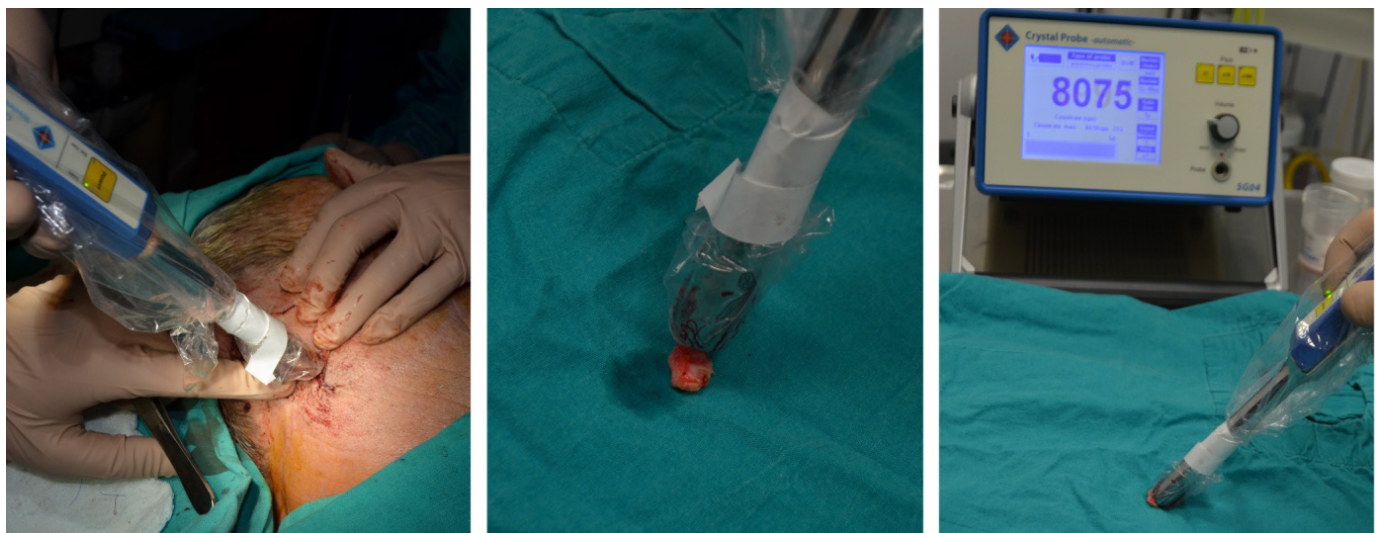


Figure 3. Sentinel lymph node biopsy procedure for melanoma.

different clinical studies with high level of evidence were focused on to clarify the role of SLN biopsy on survival. In 2006, Multicenter Selective Lymphadenectomy Trial-I (MSLT-I) study was presented by Morton et al. [25]. In this study, 1269 patients with malignant melanoma were randomized into two groups as “Observation” vs. “SLN biopsy” (Observation: 500 cases, SLN: 769 cases). There was a statistically significant difference between two groups in terms of 5-year disease-free survival (Observation: 78.3% + 1.6; SLN biopsy: 73.1 + 2.1); however, no statistically significant difference was observed for melanoma specific survival (Observation: 87.1% + 1.3; SLN biopsy: 86.6% + 1.6). In 2014, another clinical study was published in *New England Journal of Medicine* about the comparative analysis of “Observation” vs “SLN biopsy” in patients with medium and thick malignant melanoma [26]. According to this report, authors were unable to determine statistically significant difference in melanoma-specific survival in both patients with medium-malignant melanoma (Observation: 5- and 10-year survival: 85.7 ± 1.6 and 78.3 ± 2.0 vs SLN biopsy: 5- and 10-year survival: 86.6 ± 1.3 and 81.4 ± 1.5) and patients with thick-malignant melanoma (Observation: 5-, and 10-year survival: 67.5 ± 4.5 and 64.4 ± 4.6, respectively vs SLN biopsy: 5- and 10-year survival: 67.0 ± 3.7 and 58.9 ± 4.1). However, statistically significant differences were found in terms of disease-free survival in both patients with medium-malignant melanoma (Observation: 5- and 10-year survival: 72.7 ± 2.1 and 64.7 ± 2.3, SLN biopsy: 5- and 10-year survival: 77.8 ± 1.6 and 71.3 ± 1.8) and patients with thick-malignant melanoma (Observation: 5- and 10-year survival: 43.7 ± 4.7 and 40.5 ± 4.7, SLN biopsy: 5- and 10-year survival: 56.2 ± 3.9 and 50.7 ± 4.0, respectively). Therefore, SLN biopsy is recommended for the patients with tumor thickness > 0.8 mm and no lymph node involvement was detected in clinical evaluation. However, Sladden et al. criticized the reliability of MSLT-1 final report results as being the outcome of post-randomization subgroup analyses [27].

## **2. Is SLN biopsy effective in cutaneous malignant melanoma of the head and neck?**

Although SLN biopsy is recommended for the management of patients with early stage cutaneous malignant melanoma, head and neck is highly different than the other parts of the body due to complex lymphatic system and high lymph node density. A systematic review evaluated the efficacy of SLN biopsy in patients with cutaneous

malignant melanoma of the head and neck, and reported that false negativity rate was remarkably high [20.4% (3.3–44.0%)] despite of high diagnostic rate [94.0% (64.8%)] [28]. In addition, a retrospective analysis of 153 patients with cutaneous malignant melanoma of the head and neck found that the false negativity rate was 32.1%. The authors emphasized that the most important risk factor for the false negativity was the removal of a single lymph node [29]. Furthermore, aggressive malignant melanomas may spread to non-sentinel node sites, or skip sentinel nodes; hence a negative SLN biopsy does not exclude locoregional or metastatic disease. “*Final trial report of sentinel-node biopsy versus nodal observation in melanoma*” demonstrated that half or two-thirds of patients who develop metastases, had negative sentinel nodes. Consequently, the high rate of false negativity in patients who underwent SLN biopsy for malignant melanoma in the head and neck region should not be overlooked when the negative impact of regional recurrence on survival was considered.

## **3. What is the best strategy (Observation or Lymph node dissection) when a lymph node involvement was reported after SLN biopsy?**

In malignant melanoma, the application of complementary neck dissection and its role on survival after lymph node positivity at SLN biopsy has been discussed for many years. According to current The National Comprehensive Cancer Network or European guidelines, patients with SLNB-positive stage III nodal disease should undergo a complementary neck dissection and recommended as a standard of care. On the other hand despite the guideline recommendation, review of the National Cancer Data Base (2004–2005) revealed only 50% of patients with a positive SLNB undergoing complementary neck dissection [30]. There are many studies investigating the effectiveness and necessity of complementary neck dissection. However DECOD-SLT was the first clinical study with high level of evidence, in which 483 patients with malignant melanoma and SLN biopsy (+) were included. Two hundred forty one patients underwent observation and 242 patients underwent complementary neck dissection. According to this prospective multicenter randomized trial, both strategies provided similar oncological outcomes [31]. Therefore, authors emphasized that complementary lymph node dissection is not mandatory after SLN biopsy especially for patients with micrometastasis. Subsequently, Multicenter Selective Lymphadenectomy Trial-II (MSLT-II) study was

published in 2017<sup>[32]</sup>. The results of this study showed that supplemental lymph node dissection after SLN biopsy is beneficial for regional control, not for melanoma-specific survival. Therefore, authors mentioned that dissection related complications should be considered before the application of complementary neck dissection.

## Conclusion

Briefly, every surgeon should pay special attention on the following topics in patients with cutaneous malignant melanoma of the head and neck: (i) the biopsy technique

should include the tumor in full layer. (ii) the surgical margin should be determined according to the tumor thickness. (iii) a “staged excision” of primary tumor might be performed at the head and neck region. (iv) SLN biopsy should be considered/ recommended in patients with a tumor thickness > 0.8mm. (v) SLN biopsy should be applied carefully in head and neck region. (vi) In case of SLN biopsy positivity, the advantages and disadvantages of lymph node dissection should be considered and discussed with the patient.

## References

1. Boring CC, Squires TS, Tong T, Montgomery S. Cancer statistics, 1994. *CA Cancer J Clin* 1994;44(1):7-26.
2. Leiter U, Garbe C. Epidemiology of melanoma and nonmelanoma skin cancer--the role of sunlight. *Adv Exp Med Biol* 2008;624:89-103. doi: 10.1007/978-0-387-77574-6\_8
3. Whiteman DC, Green AC, Olsen CM. The Growing Burden of Invasive Melanoma: Projections of Incidence Rates and Numbers of New Cases in Six Susceptible Populations through 2031. *J Invest Dermatol* 2016;136(6):1161-71. doi: 10.1016/j.jid.2016.01.035
4. Torre LA, Bray F, Siegel RL, Ferlay J, Lortet-Tieulent J, Jemal A. Global cancer statistics, 2012. *CA Cancer J Clin* 2015;65(2):87-108. doi: 10.3322/caac.21262
5. Hacıkamiloğlu E, Gültekin M, Boztaş G, et al. Türkiye Kanser İstatistikleri. Ankara: T.C. Sağlık Bakanlığı Türkiye Halk Sağlığı Kurumu; 2017. Available from: [https://hsgm.saglik.gov.tr/depo/birimler/kanser-db/istatistik/2014-RAPOR\\_uzuuun.pdf](https://hsgm.saglik.gov.tr/depo/birimler/kanser-db/istatistik/2014-RAPOR_uzuuun.pdf).
6. Chen ST, Geller AC, Tsao H. Update on the Epidemiology of Melanoma. *Curr Dermatol Rep* 2013;2(1):24-34. doi: 10.1007/s13671-012-0035-5
7. McGovern VJ, Mihm MC, Jr, Bailly C, et al. The classification of malignant melanoma and its histologic reporting. *Cancer* 1973;32(6):1446-57.
8. Amin MB, American Joint Committee on Cancer., American Cancer Society. *AJCC cancer staging manual*. Eight edition / editor-in-chief, Mahul B. Amin, MD, FCAP; editors, Stephen B. Edge, MD, FACS and 16 others; Donna M. Gress, RHIT, CTR - Technical editor; Laura R. Meyer, CAPM - Managing editor. ed. Chicago IL: American Joint Committee on Cancer, Springer; 2017. p. xvii, 1024 pages.
9. Elder DE. Precursors to melanoma and their mimics: nevi of special sites. *Mod Pathol* 2006;19 Suppl 2:S4-20. doi: 10.1038/modpathol.3800515
10. Salerni G, Carrera C, Lovatto L, et al. Characterization of 1152 lesions excised over 10 years using total-body photography and digital dermatoscopy in the surveillance of patients at high risk for melanoma. *J Am Acad Dermatol* 2012;67(5):836-45. doi: 10.1016/j.jaad.2012.01.028
11. Network NCC. Melanoma (Version 2.2018) 2018 [08.06.2018]. Available from: [https://www.nccn.org/professionals/physician\\_gls/pdf/melanoma.pdf](https://www.nccn.org/professionals/physician_gls/pdf/melanoma.pdf).
12. Cangiarella J, Symmans WF, Shapiro RL, et al. Aspiration biopsy and the clinical management of patients with malignant melanoma and palpable regional lymph nodes. *Cancer* 2000;90(3):162-6.
13. Cha J, Kim S, Wang J, Yun M, Cho A. Evaluation of (18)F-FDG PET/CT Parameters for Detection of Lymph Node Metastasis in Cutaneous Melanoma. *Nucl Med Mol Imaging* 2018;52(1):39-45. doi: 10.1007/s13139-017-0495-4
14. Gold JS, Jaques DP, Busam KJ, Brady MS, Coit DG. Yield and predictors of radiologic studies for identifying distant metastases in melanoma patients with a positive sentinel lymph node biopsy. *Ann Surg Oncol* 2007;14(7):2133-40. doi: 10.1245/s10434-007-9399-3
15. Balch CM, Urist MM, Karakousis CP, et al. Efficacy of 2-cm surgical margins for intermediate-thickness melanomas (1 to 4 mm). Results of a multi-institutional randomized surgical trial. *Ann Surg* 1993;218(3):262-7; discussion 7-9.
16. Cohn-Cedermark G, Rutqvist LE, Andersson R, et al. Long term results of a randomized study by the Swedish Melanoma Study Group on 2-cm versus 5-cm resection margins for patients with cutaneous melanoma with a tumor thickness of 0.8-2.0 mm. *Cancer* 2000;89(7):1495-501.
17. Haigh PI, DiFronzo LA, McCready DR. Optimal excision margins for primary cutaneous melanoma: a systematic review and meta-analysis. *Can J Surg* 2003;46(6):419-26.
18. Veronesi U, Cascinelli N, Adamus J, et al. Thin stage I primary cutaneous malignant melanoma. Comparison of excision with margins of 1 or 3 cm. *N Engl J Med* 1988;318(18):1159-62. doi: 10.1056/NEJM198805053181804
19. Eskiizmir G, Gencoglan G, Temiz P, Hircin Z, Ermertcan A. Staged-surgery with permanent pathology for the management of high-risk nonmelanoma skin cancer of the nose. *Eur Arch Otorhinolaryngol* 2011;268(1):117-21. doi: 10.1007/s00405-010-1324-x
20. Moyer JS, Rudy S, Boonstra PS, et al. Efficacy of Staged Excision With Permanent Section Margin Control for Cutaneous Head and Neck Melanoma. *JAMA Dermatol* 2017;153(3):282-8. doi: 10.1001/jamadermatol.2016.4603
21. Gershenwald JE, Scolyer RA, Hess KR, et al. Melanoma staging: Evi-



- dence-based changes in the American Joint Committee on Cancer eighth edition cancer staging manual. *CA Cancer J Clin* 2017;67(6):472-92. doi: 10.3322/caac.21409
22. Pathak I, O'Brien CJ, Petersen-Schaeffer K, et al. Do nodal metastases from cutaneous melanoma of the head and neck follow a clinically predictable pattern? *Head Neck* 2001;23(9):785-90.
  23. Thom JJ, Moore EJ, Price DL, Kasperbauer JL, Starkman SJ, Olsen KD. The Role of Total Parotidectomy for Metastatic Cutaneous Squamous Cell Carcinoma and Malignant Melanoma. *JAMA Otolaryngol Head Neck Surg* 2014;140(6):548-54. doi: 10.1001/jamaoto.2014.352
  24. Agrawal S, Kane JM, 3rd, Guadagnolo BA, Kraybill WG, Ballo MT. The benefits of adjuvant radiation therapy after therapeutic lymphadenectomy for clinically advanced, high-risk, lymph node-metastatic melanoma. *Cancer* 2009;115(24):5836-44. doi: 10.1002/cncr.24627
  25. Morton DL, Thompson JF, Cochran AJ, et al. Sentinel-node biopsy or nodal observation in melanoma. *N Engl J Med* 2006;355(13):1307-17. doi: 10.1056/NEJMoa060992
  26. Morton DL, Thompson JF, Cochran AJ, et al. Final trial report of sentinel-node biopsy versus nodal observation in melanoma. *N Engl J Med* 2014;370(7):599-609. doi: 10.1056/NEJMoa1310460
  27. Sladden M, Zagarella S, Popescu C, Bigby M. No survival benefit for patients with melanoma undergoing sentinel lymph node biopsy: critical appraisal of the Multicenter Selective Lymphadenectomy Trial-I final report. *Br J Dermatol* 2015;172(3):566-71. doi: 10.1111/bjd.13675
  28. de Rosa N, Lyman GH, Silbermins D, et al. Sentinel node biopsy for head and neck melanoma: a systematic review. *Otolaryngol Head Neck Surg* 2011;145(3):375-82. doi: 10.1177/0194599811408554
  29. Miller MW, Vetto JT, Monroe MM, Weerasinghe R, Andersen PE, Gross ND. False-negative sentinel lymph node biopsy in head and neck melanoma. *Otolaryngol Head Neck Surg* 2011;145(4):606-11. doi: 10.1177/0194599811411878
  30. Bilimoria KY, Balch CM, Bentrem DJ, et al. Complete lymph node dissection for sentinel node-positive melanoma: assessment of practice patterns in the United States. *Ann Surg Oncol* 2008;15(6):1566-76. doi: 10.1245/s10434-008-9885-2
  31. Leiter U, Stadler R, Mauch C, et al. Complete lymph node dissection versus no dissection in patients with sentinel lymph node biopsy positive melanoma (DeCOG-SLT): a multicentre, randomised, phase 3 trial. *Lancet Oncol* 2016;17(6):757-67. doi: 10.1016/S1470-2045(16)00141-8
  32. Faries MB, Thompson JF, Cochran AJ, et al. Completion Dissection or Observation for Sentinel-Node Metastasis in Melanoma. *N Engl J Med* 2017;376(23):2211-22. doi: 10.1056/NEJMoa1613210

This is an open access article distributed under the terms of the Creative Commons Attribution-NonCommercial-NoDerivs 3.0 Unported (CC BY-NC-ND3.0) Licence (<http://creativecommons.org/licenses/by-nc-nd/3.0/>) which permits unrestricted noncommercial use, distribution, and reproduction in any medium, provided the original work is properly cited.

Please cite this article as: Özgür E., Karakullukçu B., Eskiizmi G., Current Treatment Strategies in Cutaneous Malignant Melanoma of the Head and Neck. *ENT Updates* 2019;9(1): 25–33