

Differential diagnosis of submandibular gland swellings

Demet Yazıcı, Mehmet Yalçın Çöktü, Zekiye Güney, Sanem Okşan Erkan,
Orhan Görgülü, İlhami Yıldırım, Osman Kürşat Arıkan

ENT Department, Adana Numune Training and Research Hospital, Adana, Turkey

Abstract

Objective: The differential diagnosis of submandibular triangle swellings can be challenging to the clinician. In this study, we retrospectively analyzed clinical and histopathological characteristics of these swellings referred to our clinic and integrated our results with current literature in terms of various diagnostic aspects.

Methods: A total number of 64 transcervical submandibular gland extirpations were reviewed and evaluated regarding age, gender, fine-needle aspiration biopsy and specimen reports.

Results: This study comprised 34 male (53.1%) and 30 female (46.9%) patients. We classified submandibular triangle swellings clinicopathologically as tumoral and non-tumoral lesions for better evaluation. We had 15 patients with primary epithelial submandibular gland neoplasm, 10 (66.7%) of them were benign cases, all of the benign cases were pleomorphic adenoma with a male to female ratio of 1:2.33 and a mean age of 30.8 years, 5 (33.3%) of them were malignant with a mean age of 55 years. There were also 37(57.8%) patients with chronic sialadenitis associated with sialolithiasis, 1 (1.6%) had acute sialadenitis, 2 (3.1%) had granulomatous sialadenitis, 2 (3.1%) had reactive cervical lymphadenopathy and 5 (7.8%) were treated for cystic lesion removal. Ultrasonography and fine needle aspiration cytology were our major diagnostic tools for differential diagnosis. Our institution's sensitivity of fine-needle aspiration cytology for identifying malignancy was 60% and the specificity was 100%.

Conclusion: Submandibular gland excision for primary lesions has relatively low incidence compared with other surgical implications. Although chronic sialadenitis caused by symptomatic sialolithiasis the most frequent indication for surgery, diverse clinical entities should be ruled out for differential diagnosis of swellings of this region.

Keywords: Submandibular gland, submaxillary gland, salivary gland calculi, submandibular gland neoplasm, pleomorphic adenoma, biopsy, fine-needle.

Özet: Submandibüler bez kitlelerinde ayırıcı tanı

Amaç: Submandibüler üçgen kitlelerinin ayırıcı tanısı klinisyen açısından sıkıntılı olabilmektedir. Biz bu çalışmamızda, kliniğimize submandibüler bez kitlesi ile başvuran hastaların klinik ve histopatolojik bulgularını retrospektif olarak analiz ettik ve bulgularımızı günümüz literatürü ile karşılaştırdık.

Yöntem: Transservikal submandibüler bez eksizyonu yapılan 64 hasta incelendi ve yaş, cinsiyet, ince iğne aspirasyon biyopsisi ve spesimen sonuçları açısından değerlendirildi.

Bulgular: Bu çalışmaya 34 erkek (%53.1) ve 30 kadın (%46.9) hasta dahil edildi. Submandibüler üçgen kitleleri; tümöral ve tümöral olmayan lezyonlar olarak ikiye ayrıldı. 15 hastada primer epitelyal submandibüler bez neoplazmı mevcuttu, bu kitlelerden 10 tanesi (%66.7) benignitti. Benign olanların hepsi pleomorfik adenomdu, hastaların ortalama yaşı 30.8 iken, erkek/kadın oranı ise 1:2.33 idi. Kitlelerden 5 tanesi (%33.3) ise malignitti. Malign olanların ortalama yaşı 55 idi. 37 (%57.8) hastada sialolitiasise bağlı kronik sialadenit mevcuttu, 1 hastada (%1.6) akut sialadenit, 2 hastada (%3.1) granülomatöz sialadenit, 2 hastada (%3.1) reaktif servikal lenfadenopati mevcuttu. 5 hastada (%7.8) ise kistik lezyon eksizyonu yapıldı. Ultrasonografi ve ince iğne aspirasyon sitolojisi ayırıcı tanıda en sık kullanılan tanısal yöntemlerdi. Malignansi saptamada ince iğne aspirasyon sitolojisinin sensitivitesi %60, spesifitesi %100 idi.

Sonuç: Submandibüler bezin primer eksizyonu, diğer endikasyonlarla karşılaştırıldığında nadirdir. Submandibüler bez eksizyonu en sık nedeni semptomatik sialolitiasise bağlı kronik sialadenit olsa bile, bu bölgenin lezyonlarının ayırıcı tanısında değişik klinik antiteler göz önünde bulundurulmalıdır.

Anahtar sözcükler: Submandibüler bez, submaksiller bez, tükürük bezi taşı, submandibüler bez neoplazmı, pleomorfik adenom, biyopsi, ince iğne.

Salivary glands exhibit a broad spectrum of diseases requiring medical or surgical intervention. The diversity of the diseases varies mainly with the localization of the glands.

Bacterial and viral infections, sialolithiasis, systemic diseases such as Sjögren syndrome and Mikulicz's disease, granulomatous diseases such as tuberculosis and actinomycosis, cys-

Correspondence: Demet Yazıcı, MD. ENT Department, Adana Numune Training and Research Hospital, Adana, Turkey.
e-mail: demetyazici@yahoo.com

Received: January 13, 2018; **Accepted:** February 22, 2018

This paper was presented orally at 18th Rhinocamp Meeting, May 17-20, 2017, Marmaris, Muğla, Turkey.

©2018 Continuous Education and Scientific Research Association (CESRA)

Online available at:
www.entupdates.org
doi:10.2399/jmu.2018001003
QR code:



deomed®

tic lesions and tumoral lesions can all be noted as miscellaneous diseases affecting these glands. As tumors are most frequent lesions of the parotid glands, sialolithiasis and inflammatory diseases are common features of the submandibular glands.^[1] The propensity of malignancy increases as the size of the gland decreases, 25% of the parotid gland neoplasms, 43% of the submandibular gland and 82% of the minor salivary gland neoplasms are reported as malignant in the literature.^[2]

Plain radiographs, ultrasonography, conventional sialography, sialoendoscopy, computed tomography (CT), magnetic resonance imaging (MRI), MRI sialography, digital subtraction X-ray sialography and fine-needle aspiration cytology (FNAC) may all be used for differential diagnosis of the salivary gland lesions.^[3,4] Ultrasonography, conventional or transoral, combined with CT is the most preferred modality for identifying sialoliths of the salivary glands.^[5] FNAC is recommended for neoplastic lesions and has a high accuracy for determining malignancy.^[6]

The aim of our study is to review our six-year clinical experience with submandibular gland excision and discuss our findings regarding differential diagnosis. We analyzed patients according to their genders, histopathological results, age intervals and complications and correlated our results in the light of the current literature.

Materials and Methods

In this retrospective study, we analyzed 63 patients undergoing 64 transcervical submandibular gland extirpations between January 2011 and December 2016 in our tertiary center. We evaluated patients according to their age, gender, preoperative assessment, fine-needle aspiration biopsy results, specimen reports and complications after the surgery. The ethics committee approval was taken from our own institution's ethics committee (No: 26/2017).

Histopathological, cytological diagnosis and TNM classification of submandibular gland neoplasms were based on the World Health Organization (WHO) classification of tumors: pathology & genetics, head and neck tumors (salivary glands) for benign and malignant neoplasms.^[7] We used the statistical package SPSS (version 20.0) for statistical evaluation including χ^2 test and a value of $p < 0.05$ was defined as statistical significance.

Results

A total number of 64 submandibular gland excision patients, 34 males (53.1%) and 30 females (46.9%) were enrolled in

this study. The ages of the patients ranged in between 1 to 75 years with a mean age of 37.5 ± 16.65 . Fifty-two percent of the patients had right-sided mass, and forty-eight percent had left-sided mass. One patient was operated on both sides. We classified submandibular lesions clinicopathologically as tumoral and non-tumoral lesions (**Fig. 1**). Of the 15 (23.4%) primary epithelial submandibular gland tumor patients, there were 10 (66.7%) benign cases and 5 (33.3%) malignant cases and our overall benign/malignant ratio was 2:1. The median age for benign tumors was 30.8 years, for malignant tumors was 55 years with an overall male to female (M:F) of 1:2.75. We also had two male patients diagnosed as having non-Hodgkin lymphoma (NHL). Forty-seven patients (73.4%) had non-tumoral submandibular gland lesions, 37 of them had (57.8%) chronic sialadenitis associated with sialolithiasis, 1 patient (1.6%) had acute sialadenitis, 2 patients (3.1%) had granulomatous sialadenitis, 2 of them (3.1%) had reactive cervical lymphadenopathy and 5 patients (7.8%) were treated for cystic lesion removal. The median age of 37 chronic sialadenitis associated with sialolithiasis patients was 39.6 years where 23 (62.2%) of them were male and 14 (37.8%) of them were female with a male to female (M:F) ratio of 1.6:1. Of the 5 cystic lesions, 2 had plunging ranula, 1 had benign lymphoepithelial cyst, 1 had epidermal keratinous cyst and 1 patient had salivary duct cyst (**Table 1**).

Ultrasonography was our first and major diagnostic tool for evaluating submandibular gland (SG) diseases. Sialolithiasis was detectable with ultrasonography in 82.14% patients and FNAC was performed on patients presenting with SG mass. CT and MRI were used as supplementary diagnostic tools for sialolithiasis, SG masses and cysts. Painful recurrent swelling was the main complaint for sialolithiasis and painless mass in the neck was the major complaint for SG masses.

Our correlation between fine-needle aspiration cytology and final histopathological diagnosis is presented in **Table 2**. The sensitivity of FNAC for identifying malignancy was 60% and the specificity was 100%. Positive predictive value (PPV) was 100% and negative predictive value (NPV) was 83.3%. Malignity prevalence was 33.3% and the overall FNAC accuracy was 86.7%.

Additional to submandibular gland excision, we performed supraomohyoid neck dissection and functional neck dissection for the malignant tumors. Our most common postsurgical complication was temporary marginal mandibular nerve palsy which developed in 3 (4.6%) patients. Moreover, one (1.6%) patient with orocutaneous

fistulareoperated three months after surgery. One patient was treated for neck abscess and one for sialocele after SG excision.

Discussion

Granulomatous lymphadenopathy caused by tuberculosis and sarcoidosis, various cystic entities such as branchial cleft cysts and ranula, primary neoplastic and metastatic tumors, lymphomas, suppurativesialadenitis caused by sialolithiasis should all be evaluated for the differential diagnosis of the submandibular triangle swellings.^[8,9] In this study, we classified submandibular gland diseases as tumoral and non-tumoral lesions for better assessment (Fig. 1).

Chronic sialadenitis caused by symptomatic sialolithiasis is the most commonly encountered indication for submaxillectomy.^[1,10] In our study, our sialolithiasis rate was 57.8%, comprised of mainly male patients between 4th and 6th decades of life. Our youngest sialolithiasis patient was a 14-year-old male, the oldest one was a 58-year-old male and one male patient was operated for bilateral sialolithiasis (2.7%).

The higher incidence of SG sialolithiasis between 3rd to 6th decades of life is also mentioned in the literature which was also consonant with our study’s results.^[11,12] 80% to 90% of salivary stones are formed in the submandibular glands instead of parotid glands because of the anatomical properties of the Wharton duct and biochemical properties of saliva excreted by the glands.^[12,13] The more viscous saliva of the SG having higher pH and higher calcium concentration compared with parotid gland (pH 6.5 vs pH 5.8) and the longer course of the Wharton duct against gravity causing stasis of the salivary flow lead to predisposition of the formation of stones.^[12-14] Our M:F ratio was 1,6:1 demonstrating male predilection in this study. Although there are conflicting reports, the male predominance is a consensus on the SG sialolithiasis.^[11,12,15,16] Besides the general concept of no side predilection in SG sialolithiasis, our sialolithiasis patients showed a higher right-sided incidence (59.5% vs 40.5%) which is also remarked in literature.^[12,13,15] Our bilaterality incidence was 2.7% which was in concordance with the literature.^[12,13] Ultrasonography was our major diagnostic tool to avoid radiation exposure.^[4] Transoral and transcervical

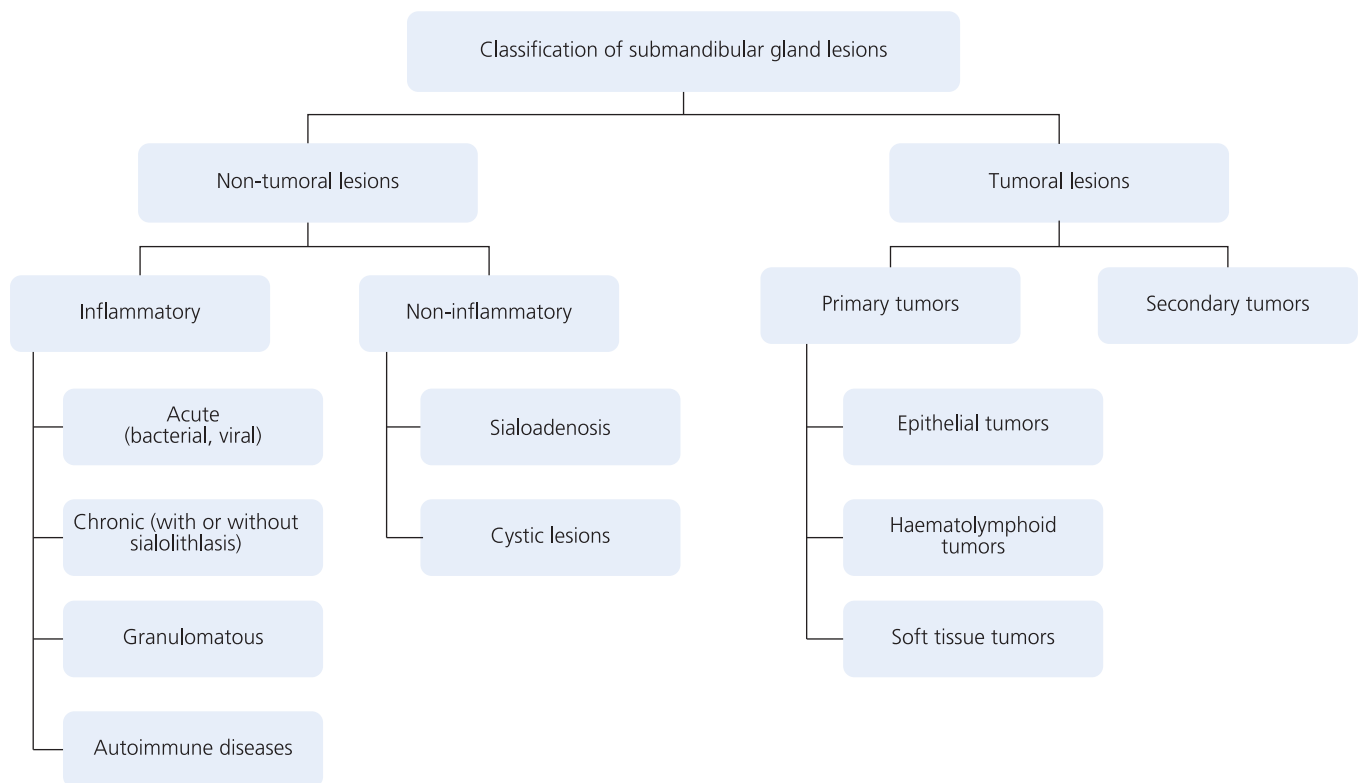


Fig. 1. Classification of submandibular gland lesions.

Table 1. Histopathological classification of the submandibular gland lesions and their distribution according to frequency, median age, percentage and gender.

Histopathological classification of submandibular gland lesions	Frequency	Percentage in total	Median age (range)*	Gender	
				Male	Female
Pleomorphic adenoma	10	15.6	30.8 (10–61)	3 (30%)	7 (70%)
Adenoid cystic carcinoma	2	3.1	42 (40–44)	1 (50%)	1 (50%)
Squamous cell carcinoma	1	1.6	75	0	1 (100%)
Malignant mixt tumor	1	1.6	60	0	1 (100%)
Carcinoma ex-pleomorphic adenoma	1	1.6	56	0	1 (100%)
Chronic sialadenitis associated with sialolithiasis	37	57.8	39.6 (14–58)	23 (62.2%)	14 (37.8%)
Acute sialadenitis	1	1.6	1	1 (100%)	0
Granulomatous sialadenitis	2	3.1	14 (12–16)	1 (50%)	1 (50%)
Plunging ranula	2	3.1	13.5 (13–14)	0	2 (100%)
Salivary duct cyst	1	1.6	19	1 (100%)	0 (100%)
Epidermal keratinous cyst	1	1.6	18	1 (100%)	0
Benign lymphoepithelial cyst	1	1.6	63	1 (100%)	0
Non-Hodgkin lymphoma	2	3.1	64.5 (64–65)	2 (100%)	0
Reactive cervical lymphadenopathy	2	3.1	33 (29–37)	0	2 (100%)
Total	64	100	37.5±16.65 (1–75)	34 (53.1%)	30 (46.9%)

*Years.

extirpation of the submandibular gland, intraoral excision of the sialolith and sialoendoscopy are the general methods for treating submandibular sialolithiasis, but in this study we only included patients with transcervical extirpation.

Pleomorphic adenoma was the most prevalent tumor of our review and adenoidcystic carcinoma was the most common malignant tumor which were all consistent with the literature.^[1,8] All of our patients presenting with SG mass had fine-needle aspiration cytology before the final operation. We had 10 pleomorphic adenoma patients which were all diagnosed correctly with FNAC. Overall, FNAC specified 86.7% correct diagnosis. Of our five primary malignant SG patients, one carcinoma ex-pleomor-

phic adenoma patient and one malignant mixt tumor patient were misdiagnosed with FNAC and reported as having pleomorphic adenoma. These two tumors are the two different forms of malignant transformation of pleomorphic adenomas and repeated aspirations from different areas of the mass should be performed in case of malignancy suspicion for avoiding misdiagnosis. In our study, our sensitivity of FNAC for malignant lesions was 60% and our specificity was 100%. Despite wide range of outcomes in the current literature, the specificity of FNAC of salivary glands for identifying malignancy is predominantly higher than the sensitivity which was also consistent with our findings.^[17,18]

Table 2. Our institution's correlation between fine needle aspiration cytology results and final histopathological diagnosis for primary epithelial submandibular gland neoplasms.

	Histopathologically malignant	Histopathologically benign	
FNA malignant	3 (true positive)	0 (false positive)	Positive predictive value 100%
FNA benign	2 (false negative)	10 (true negative)	Negative predictive value 83.3%
	Sensitivity 60%	Specificity 100%	Malignancy prevalence (33.3%) FNAC accuracy (86.7%) Total = 15

Our malignancy rate was 33.3% in this study. Also, for primary submandibular gland neoplasms, our M:F ratio was 1:2.75 demonstrating a female prominence. Our mean age of patients with pleomorphic adenoma was 30.8 years and with malignant tumors was 55 years. Our youngest pleomorphic adenoma patient was a 10-year-old female and the oldest one was a 61-year-old female (**Table 1**). Unfortunately, our study group for primary submandibular gland neoplasms was too small to end up with any conclusions, but our findings were consistent with the literature. The malignancy rate of SG lesions varies from 40% to 70% in miscellaneous studies demonstrating higher malignancy rate compared with parotid lesions.^[1,2,19] The female predominance for benign SG lesions and male predominance for malignant lesions are also implied in various series.^[19,20]

Besides sialolithiasis and neoplastic lesions, non-neoplastic cystic lesions such as lymphoepithelial cysts, mucus retention cysts and epidermal cysts should also be considered as differential diagnosis. Various neoplastic diseases such as Warthin's tumor, pleomorphic adenomas with cystic degeneration, acinic cell carcinomas, mucoepidermoid carcinomas, cystadenoma malignant mixed tumors and cystadenocarcinomas may also demonstrate cystic changes and may cause misinterpretation of FNAC.^[21,22]

We also had two patients with granulomatous sialadenitis caused by tuberculosis. In addition to mycobacterial infections, ductal obstruction caused by calculi or carcinoma, sarcoidosis, cat-scratch disease, tularemia, toxoplasmosis and systemic diseases such as Wegener's granulomatosis and Crohn's disease may also cause granulomatous sialadenitis and should not be overlooked both by the clinician and the pathologist.^[23,24]

Two of our elderly male patients in their seventh decade were diagnosed with non-Hodgkin lymphoma. Primary haematolymphoid tumors of the salivary gland are rare neoplasms consisting mainly of B-cell NHLs. One of our patients was diagnosed with diffuse large B-cell lymphoma and the other with mantle cell lymphoma. The majority of NHLs affect the parotid gland (75%), and the rest mainly arise in the submandibular gland. Adjuvant chemoradiotherapy is the treatment of choice for these patients where the survival rate is lowest for diffuse large B-cell lymphoma.^[25,26]

In this current study, all our patients diagnosed with sialolithiasis and benign tumors had undergone transcervical extirpation of the submandibular gland. Additional prophylactic neck dissection had been performed on patients during the surgery when FNAC indicated malignancy or after the surgery when the final specimen report was malignant.

Patients received adjuvant radiotherapy and/or chemotherapy by the oncologists. Due to the close relationship between the gland and the lingual, hypoglossal and the marginal mandibular branch of the facial nerve, facial artery, anterior facial vein and lingual artery, meticulous care should be taken during extirpation of the submandibular gland to avoid complications such as transient or permanent paralysis of marginal mandibular nerve, lingual nerve and hypoglossal nerve, hematomas, seromas, salivary fistulas and sialoceles.^[27] Of our six patients with complications, 3 (4.7%) of them had transient palsy of the mandibular branch of the facial nerve, one patient (1.6%) with malignant lesion had permanent paralysis of marginal mandibular nerve, one patient (1.6%) who had undergone functional neck dissection developed neck abscess, one patient (1.6%) with salivary fistula was re-operated for fistula excision and developed transient marginal mandibular nerve palsy, one patient (1.6%) was treated for sialocele. We didn't have any complications considering lingual or hypoglossal nerve. Our total complication rate was 9.4% which was in concordance with literature.^[1,27]

Conclusion

In the 6-year retrospective study, we analyzed patients undergoing transcervical excision of submandibular gland according to their age, gender, FNAC findings, final specimen reports and surgical complications and discussed our findings with the current literature. Chronic sialadenitis caused by symptomatic sialolithiasis was the most common indication for gland surgery prevail among males in 4th and 6th decades of life, followed by pleomorphic adenoma of the gland which was prevalent in females starting from the 2nd decade of life. Ultrasonography and FNAC were our two major methods for diagnosis of gland lesions. We performed FNAC before all neoplastic lesions and our FNAC was 86.7%. Our high malignancy rate (33.3%) of primary tumors was consistent with current literature. Transient palsy of the marginal mandibular nerve was the main complication of our surgery.

Conflict of Interest: No conflicts declared.

References

1. Preuss S, Klusmann J, Wittekindt C, Drebbler U, Beutner D, Guntinas-Lichius O. Submandibular gland excision: 15 years of experience. *J Oral Maxillofac Surg* 2007;65:953–7.
2. Spiro RH. Salivary neoplasms: overview of a 35-year experience with 2,807 patients. *Head Neck Surg* 1986;8:177–84.
3. Kalinowski M, Heverhagen JT, Rehberg E, Klose KJ, Wagner HJ. Comparative study of MR sialography and digital subtraction

- sialography for benign salivary gland disorders. *AJNR Am J Neuroradiol* 2002;23:1485–92.
4. Goncalves M, Schapher M, Iro H, Wuest W, Mantsopoulos K, Koch M. Value of sonography in the diagnosis of sialolithiasis: comparison with the reference standard of direct stone identification. *J Ultrasound Med* 2017;36:2227–35.
 5. Thomas WW, Douglas JE, Rassekh CH. Accuracy of ultrasonography and computed tomography in the evaluation of patients undergoing sialendoscopy for sialolithiasis. *Otolaryngol Head Neck Surg* 2017;156:834–9.
 6. Feinstein AJ, Alonso J, Yang SE, St John M. Diagnostic accuracy of fine-needle aspiration for parotid and submandibular gland lesions. *Otolaryngol Head Neck Surg* 2016;155:431–6.
 7. Barnes L, Eveson JW, Reichart P, Sidransky D (Eds.). *World Health Organization classification of tumours. Pathology and genetics of head and neck tumours*. Lyon: IARC Press; 2005.
 8. Dalgic A, Karakoc O, Karahatay S, et al. Submandibular triangle masses. *J Craniofac Surg* 2013;24:e529–31.
 9. Kumar T, Puri G, Aravinda K, et al. Submandibular swelling: a case report with differential diagnosis. *Universal Research Journal of Dentistry* 2015;5:103–6.
 10. Papaspyrou G, Werner JA, Sesterhenn AM. Transcervical extirpation of the submandibular gland: the University of Marburg experience. *Eur Arch Otorhinolaryngol* 2014;271:2009–12.
 11. İriz A, Açıkalın A, Acar A, Boynueğri S, Eryılmaz A. Submandibular bez kitlelerine yaklaşımımız. *Kulak Burun Boğaz ve Baş Boyun Cerrahisi Dergisi* 2011;19:66–9.
 12. Lustmann J, Regev E, Melamed Y. Sialolithiasis. A survey on 245 patients and a review of the literature. *Int J Oral Maxillofac Surg* 1990;19:135–8.
 13. Huoh KC, Eisele DW. Etiologic factors in sialolithiasis. *Otolaryngol Head Neck Surg* 2011;145:935–9.
 14. Adlkofer F, Thurau K. *Effects of nicotine on biological systems*. Basel, Switzerland: Birkhauser Verlag; 1991.
 15. Mela F, Berrone S, Giordano M. Clinico-statistical considerations of submandibular sialolithiasis. [Article in Italian] *Minerva Stomatol* 1986;35:571–3.
 16. McKenna J, Bostock D, McMenamin PG. Sialolithiasis. *Am Fam Physician* 1987;36:119–25.
 17. Díaz KP, Gerhard R, Domingues RB, et al. High diagnostic accuracy and reproducibility of fine-needle aspiration cytology for diagnosing salivary gland tumors: cytohistologic correlation in 182 cases. *Oral Surg Oral Med Oral Pathol Oral Radiol* 2014;118:226–35.
 18. P A, C A, Masilamani S, Jonathan S. Diagnosis of salivary gland lesions by fine needle aspiration cytology and its histopathological correlation in a tertiary care center of southern India. *J Clin Diagn Res* 2015;9:EC07–10.
 19. Weber RS, Byers RM, Petit B, Wolf P, Ang K, Luna M. Submandibular gland tumors. Adverse histologic factors and therapeutic implications. *Arch Otolaryngol Head Neck Surg* 1990;116:1055–60.
 20. Camilleri IG, Malata CM, McLean NR, Kelly CG. Malignant tumours of the submandibular salivary gland: a 15-year review. *Br J Plast Surg* 1998;51:181–5.
 21. Layfield LJ, Gopez EV. Cystic lesions of the salivary glands: cytologic features in fine-needle aspiration biopsies. *Diagn Cytopathol* 2002;27:197–204.
 22. Orell SR, Nettle WJS. Fine needle aspiration biopsy of salivary gland tumours. Problems and pitfalls. *Pathology* 1988;20:332–7.
 23. Batsakis JG. Granulomatous sialadenitis. *Ann Otol Rhinol Laryngol* 1991;100:166–9.
 24. van der Walt JD, Leake J. Granulomatous sialadenitis of the major salivary glands. A clinicopathological study of 57 cases. *Histopathology* 1987;11:132–44.
 25. Abuel-Haija M, Czader M. Salivary gland lymphomas. In: Al-Abbadi MA, editor. *Salivary gland cytology*. New York: Wiley? Blackwell; 2011. p. 187–214.
 26. Gleeson MJ, Bennett MH, Cawson RA. Lymphomas of salivary glands. *Cancer* 1986;58:699–704.
 27. Hernando M, Echarri RM, Taha M, Martin-Fragueiro L, Hernando A, Mayor GP. Surgical complications of submandibular gland excision. *Acta Otorrinolaringol Esp* 2012;63:42–6.

This is an open access article distributed under the terms of the Creative Commons Attribution-NonCommercial-NoDerivs 3.0 Unported (CC BY-NC-ND3.0) Licence (<http://creativecommons.org/licenses/by-nc-nd/3.0/>) which permits unrestricted noncommercial use, distribution, and reproduction in any medium, provided the original work is properly cited.

Please cite this article as: Yazıcı D, Çöktü MY, Güney Z, Erkan SO, Görgülü O, Yıldırım İ, Arıkan OK. Differential diagnosis of submandibular gland swellings. *ENT Updates* 2018;8(1):56–61.