

Topical dexpanthenol application improves healing of acute tympanic membrane perforations: an experimental study

Sinem Demirdelen¹, Mehmet İmamoğlu¹, Selçuk Arslan¹, İsmail Saygın²

¹Department of Otorhinolaryngology - Head and Neck Surgery, School of Medicine, Karadeniz Technical University, Trabzon, Turkey

²Department of Pathology, School of Medicine, Karadeniz Technical University, Trabzon, Turkey

Abstract

Objective: To investigate the healing effects of topical dexpanthenol on acute tympanic membrane (TM) perforations in rats through observations of healing time and histopathological changes.

Methods: A total of 20 Sprague-Dawley rats were included in the study. Every perforation was formed at the pars tensa of TMs with a size 2 mm in diameter. The right TM of each rat was treated with topical dexpanthenol for 2 days (treatment group); on the other hand, no topical agent was applied on the left TMs of rats (sham group). All TMs were examined under otomicroscopy at the third, fifth, and seventh days to determine the healing of TM perforations. Moreover, TMs were histopathologically examined to assess neovascularization, collagenization, fibroblastic activity, inflammatory cell positivity at the lamina propria (LP) layer of TMs.

Results: The TM perforations in the treatment group healed significantly earlier ($p<0.05$). The collagenization at LP was significantly higher in the treatment group ($p<0.05$), while neovascularization and inflammatory cell positivity were significantly higher in the sham group ($p<0.05$). The fibroblastic activity was higher in the treatment group although no statistically significant difference was determined.

Conclusion: The findings of the current study suggest that dexpanthenol may accelerate the healing of acute TM perforation.

Keywords: Dexpanthenol, tympanic membrane perforation, rat, wound healing.

Özet: Topikal dekspantenol uygulaması akut kulak zarı perforasyonlarının iyileşmesini hızlandırmaktadır: Deneysel bir çalışma

Amaç: Bu çalışmanın amacı, sıçanlarda akut kulak zarı (KZ) perforasyonunda topikal dekspantenol uygulamasının iyileştirici etkilerini iyileşme süresi ve histopatolojik değişikliklerin gözlenmesi ile araştırmaktır.

Yöntem: Yirmi adet Sprague-Dawley cinsi sıçanın her iki KZ'nin pars tensa bölgesinde 2 mm genişliğinde perforasyon oluşturuldu. Sıçanların sağ kulaklarındaki perforasyonlar (tedavi grubu) 2 gün boyunca topikal dekspantenol ile tedavi edildi. Sol kulaklara (sham grubu) hiçbir topikal tedavi verilmedi. Kulak zarı perforasyonlarının kapanma durumunu değerlendirmek için sıçanlar üçüncü, beşinci ve yedinci günlerde otomikroskopi ile değerlendirildi. Histopatolojik olarak kulak zarları, lamina propria tabakasındaki neovaskülarizasyonu, fibroblastik aktiviteyi, inflamatuvar hücre pozitifliğini ve kollajenizasyonu değerlendirmek için incelendi.

Bulgular: Tedavi grubunda KZ perforasyonları istatistiksel olarak anlamlı düzeyde erken iyileşti ($p<0.05$). Lamina propria kollajenizasyonu tedavi grubunda anlamlı derecede yüksek bulunurken ($p<0.05$), neovaskülarizasyon ve inflamatuvar hücre pozitifliği tedavi verilmeyen grupta anlamlı derecede yüksekti ($p<0.05$). Fibroblastik aktivite tedavi grubunda daha yüksek bulunmasına rağmen fark istatistiksel olarak anlamlı değildi.

Sonuç: Bu çalışmanın bulguları, akut kulak zarı perforasyonunun iyileşmesini hızlandırmada dekspantenolün etkin olduğunu göstermektedir.

Anahtar sözcükler: Dekspantenol, kulak zarı perforasyonu, sıçan, yara iyileşmesi.

Tympanic membrane (TM) perforation is a relatively common problem. Its incidence is not known exactly; however, estimated to be less than 1%.^[1]

The leading cause of acute TM perforations is middle ear infections, followed by trauma. Various types of traumatic insults (e.g., insertion of objects into the ear canal,

Correspondence: Selçuk Arslan, MD. Department of Otorhinolaryngology - Head and Neck Surgery, School of Medicine, Karadeniz Technical University, Trabzon, Turkey.
e-mail: selcukars@yahoo.com

Received: June 27, 2016; **Accepted:** July 23, 2016

Online available at:
www.entupdates.org
doi:10.2399/jmu.2016003007
QR code:



concussion caused by an explosion or open-handed slap, head trauma, barotrauma and iatrogenic trauma due to myringotomy, irrigation, or foreign body removal) can cause acute TM perforations. Most TM perforations, especially those caused by trauma, heal spontaneously. However, in a small group of patients, the TM perforations remain open and surgical intervention is needed.^[2]

Complex biological mechanisms play a role in the healing process of acute TM perforations including epithelial proliferation, migration, fibroblast proliferation, angiogenesis, and tissue remodeling.^[3] Various agents and treatment methods have been used with the aim of accelerating the spontaneous healing process and aiding the completeness of TM closure. The effects of topical agents, such as hyaluronic acid, heparin, epidermal growth factor (EGF), and basic fibroblast growth factor (bFGF), on the closure of TM perforations have been investigated.^[4-7] Although positive results were found with these agents, limited availability and high costs currently prevent their widespread use.

Dexpanthenol is an alcoholic analog of pantothenic acid (vitamin B5), which is a component of coenzyme A. In the body, it is converted to the active form, pantothenic acid, an essential molecule for human epithelial cells. Topical dexpanthenol has high tissue penetration, and due to its prominent effects such as stimulation of epithelialization and granulation, its efficacy in wound healing is well established.^[8]

Therefore, through examination of the closure time of TM perforations and of the histopathological changes in regenerated membranes, we aimed to investigate the efficacy of topical dexpanthenol in the healing of acute TM perforations in a rat model.

Materials and Methods

This study was performed in the Laboratory of Experimental Studies of Karadeniz Technical University School of Medicine and complied with the guidelines for the care and use of experimental animals. The approval of the local ethics committee of Karadeniz Technical University was obtained before the study was conducted. Twenty-two adult male Sprague-Dawley rats, each weighing between 250 and 300 g, were involved in the study. Animals were housed in 50±10% humidity at 22±1 °C on a 12-hour light-dark cycle and had free access to water and standard dry pellets.

Four ears (2 rats) were used as the control group. The other 20 animals were anesthetized with intraperitoneal

(IP) ketamine hydrochloride (50 mg/kg) and xylazine hydrochloride (10 mg/kg). A 2 mm perforation was created by a myringotomy knife at the posterosuperior quadrant of the pars tensa in each TM of 20 rats using an otomicroscope (Deca 21; Inami Corp., Tokyo, Japan). During the procedure, 3 rats were observed to have serious middle ear effusion in one side and were excluded from the study. The study was completed with a total of 19 rats. The right TM perforations were treated with 5 drops of dexpanthenol immediately after perforation, and additional applications of 5 drops were administered after 24 hours and after 48 hours. No treatment was given to the left ears (sham group), and the left TMs were allowed to spontaneously heal. The four TMs of the 2 rats that were not perforated were not treated, serving as a reference for the comparison of histopathological changes evaluated in the dexpanthenol and sham groups.

Otomicroscopic examination under IP ketamine anesthesia was performed on the third, fifth, and seventh days to check the status of the myringotomy patency on each side. The healing of TM perforations was evaluated as total or partial closure.

On the fourteenth day of the study, the rats were sacrificed by decapitation under anesthesia with IP ketamine hydrochloride (90 mg/kg) and xylazine hydrochloride (10 mg/kg). The tympanic bullae were opened, and the right and left TMs were removed. The specimens were kept in 10% formaldehyde solution. After 24 hours, the 38 specimens were decalcified in formic acid and sodium citrate. For both treatment and sham groups, the TM specimens were bisected through the center of the healed perforation and embedded in paraffin blocks. The TMs of the controls were bisected medially. For histopathological examination, 5 µm thick sections were stained in hematoxylin and eosin and examined under light microscopy at a 40× magnification (Olympus BX51; Olympus Corp., Tokyo, Japan). The changes in LP, including neovascularization of the lamina propria (LP), fibroblastic activity, collagenization, and inflammatory cell presence were evaluated, referencing the findings to the control TMs. The LP changes were evaluated as positive if they were prominent and as negative if there were no differences compared to the control TM specimens. All specimens were evaluated by the same pathologist.

The statistical analysis of the data regarding the histopathological changes in the LP and the TM-perforation healing time was conducted using Fischer's exact chi-square test. A p value of less than 0.05 was considered statistically significant.

Results

All TMs in the treatment and sham groups were found to be completely closed on the seventh day. The mean perforation closure time was 5.6 ± 1.4 days in the sham group and 4.4 ± 1.2 days in the dexpanthenol treatment group (Fig. 1). The difference in healing time between two groups was statistically significant ($p < 0.05$).

A comparison of the LP changes in the treatment and sham groups is shown in Table 1. The LP collagenization in the treatment group was significantly higher than sham group ($p < 0.05$) (Table 1). In the sham group, LP neovascularization and inflammatory cell positivity were significantly higher than in the treatment group ($p < 0.05$). The LP fibroblastic activity was higher in the treatment group, however the difference between both groups was not statistically significant ($p > 0.05$).

Discussion

This study showed that the healing time of the TM perforations in the dexpanthenol-treated ears was significantly shorter than in the untreated ears. The LP collagenization was also significantly higher in the treatment group, while neovascularization and inflammatory cell positivity were significantly higher in the sham group.

The healing of a traumatic perforation of the TM is a complex process that requires epithelial proliferation and migration, fibroblast proliferation, neovascularization, and tissue remodeling.^[9,10] In the typical wound healing of soft tissues, the formation of granulation tissue precedes epithelization. On the contrary, the key mechanism in the healing of TM perforations is the initial closure of the epithelial layer by increased mitotic activity of epithelial cells, followed by the regeneration of the LP.

In experimental studies, it has been reported that various topical agents may accelerate the healing of acute TM perforation. Among these agents, polypeptide growth factors have been widely studied with promising results in TM healing. In guinea pigs, bFGF was reported to promote healing of TM perforations by inducing neovascularization, fibroblast proliferation, and matrix deposition compared with controls.^[7] In other studies investigating experimental models of acute TM perforations, a shorter healing time was reported in bFGF-treated groups.^[11-13] EGF and transforming growth factor- β 1 (TGF- β 1) were found to stimulate TM-perforation healing in animal models.^[14,15]

Table 1. The comparison of LP changes in the treatment and sham groups.

		Sham group		Treatment group		Chi square	p
		n	(%)	n	(%)		
LP neovascularization	-	2	11.8	9	52.9	4.838	0.028
	+	15	88.2	8	47.1		
LP fibroblastic activity	-	5	29.4	1	5.9	1.821	0.177
	+	12	70.6	16	94.1		
LP inflammatory cells	-	6	35.3	16	94.1	10.432	0.001
	+	11	64.7	1	5.9		
LP collagenization	-	14	82.4	4	23.5	9.563	0.002
	+	3	17.6	13	76.5		

Dexpanthenol is known for promoting wound healing and epithelization, especially in dermatological conditions, such as epidermal wounds, burn injuries, and various skin irritations (e.g., scaling, pruritus, fissures, erythema). Pantothenic acid, the active form of dexpanthenol, is an essential ingredient for epithelial function.^[8] In vivo and in vitro studies with dexpanthenol have shown that it has a key role in wound-healing by activating the fibroblast proliferation.^[8] The prominent effects of dexpanthenol formulations that accelerate healing processes are the stimulation of epithelization and granulation.

In the field of otorhinolaryngology, beneficial effects of dexpanthenol were found for rhinitis sicca treatment and nasal mucosa regeneration after nasal surgeries.^[16,17] To the best of our knowledge, this is the first study in which the role

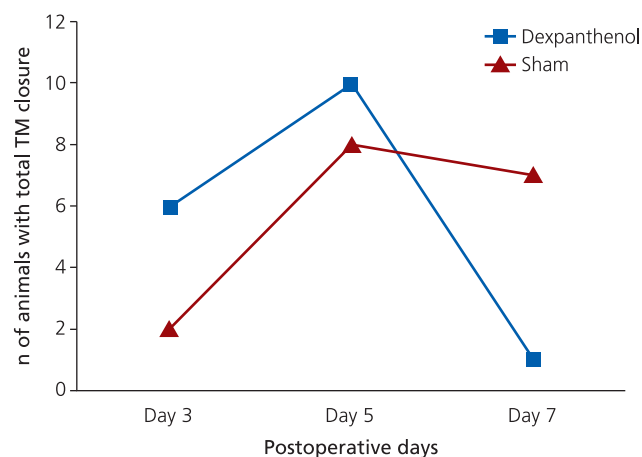


Fig. 1. The closure time (days) of TM perforations in dexpanthenol treatment and sham groups.

of topical dexpanthenol application on healing of TM perforation and LP changes was evaluated. Our findings demonstrate the beneficial effects of dexpanthenol for TM-perforation healing, as indicated by significantly shorter TM-perforation closure time and higher LP fibroblastic activity and collagenization following dexpanthenol treatment.

In the only study using dexpanthenol in a TM-perforation model, Özel et al.^[18] investigated the effects of dexpanthenol, hydrogen peroxide (H₂O₂), and erdosteine on myringosclerosis development and TM healing time. The authors found significantly less myringosclerosis in the dexpanthenol and erdosteine groups than in the control, isotonic, and H₂O₂ groups. Consistent with our findings, they also showed that TM-perforation healing time was significantly shorter in the dexpanthenol and erdosteine treatment groups.

In the current study, the effects of dexpanthenol on healing of acute TM perforation were investigated. The finding shows that the TM-perforation closure time was significantly shorter in the dexpanthenol-treated group which is consistent with the findings in previous literature^[18] and can be attributed to the stimulation of epithelization by dexpanthenol. Consistent with previous studies,^[7-10] the significant collagenization and higher fibroblastic activity in the LP in the dexpanthenol group demonstrate the wound-healing promoting effect of the molecule. Unexpectedly, we found that the LP neovascularization and inflammatory cell positivity was significantly higher in the sham group. This finding is in contrast with the findings of previous studies that revealed increased neovascularization and inflammatory cell infiltration with dexpanthenol treatment.^[8,19] However, these dexpanthenol studies were performed in wound healing models in different tissues. The healing of the TM, unlike that of other tissues, is characterized by an initial epithelial migration followed by LP regeneration. This migration and regeneration may contribute to the different healing pattern found in our study. Additionally, the anti-inflammatory effects of dexpanthenol described in previous studies^[8,20] could contribute to decreased neovascularization and inflammatory cell infiltration. However, it is controversial whether dexpanthenol, due to its anti-inflammatory action, inhibited neovascularization and inflammatory cell infiltration in the LP in our experimental model or not.

Conclusion

The clinical and histopathological findings of this study demonstrated that topical dexpanthenol application may

promote the healing of TM perforations. We suggest that topical dexpanthenol, as a readily available and simple agent, may be a reasonable alternative to surgery in treating acute traumatic TM perforations.

Conflict of Interest: No conflicts declared.

References

1. Cohen D, Tamir D. The prevalence of middle ear pathologies in Jerusalem school children. *Am J Otol* 1989;10:456-9.
2. Hellstrom S, Laurent C. Hyaluronan and healing of tympanic membrane perforations. An experimental study. *Acta Otolaryngol Suppl* 1987;42:54-61.
3. Ishibashi T, Shinogami M, Ishimoto SI, Yoshida K, Kaga K. Induction of KGF, basic FGF, and TGF α mRNA expression during healing of experimental TM perforations. *Acta Otolaryngol* 1998;118:701-4.
4. Laurent C, Hellstrom S, Fellenius E. Hyaluronan improves the healing of experimental tympanic membrane perforations. A comparison of preparations with different rheologic properties. *Arch Otolaryngol Head Neck Surg* 1998;114:1435-41.
5. Spandow O, Hellstrom S. Healing of tympanic membrane perforation—a complex process influenced by a variety of factors. *Acta Otolaryngol Suppl* 1992;492:90-3.
6. Amoils CP, Jackler RK, Lustig LR. Repair of chronic tympanic membrane perforations using epidermal growth factor. *Otolaryngol Head Neck Surg* 1992;107:669-83.
7. Dere H, Ünal A, Özcan İ, Yardımcı S, Ergül G, Titiz A, Aksoy F. Travmatik timpan membran perforasyon iyileşmesinde basic fibroblast growth faktorün etkisinin histolojik incelenmesi. *Türk Otolarengoloji Arşivi* 1997;35:33-7.
8. Ebner F, Heller A, Rippke F, Tausch I. Topical use of dexpanthenol in skin disorders. *Am J Clin Dermatol* 2002;3:427-33.
9. Johnson AP, Smallman LA, Kent SE. The mechanism of healing of tympanic membrane perforations. A two-dimensional histological study in guinea pigs. *Acta Otolaryngol* 1990;109:406-15.
10. Stenfors LE, Carlsoo B, Salen B, Winblad B. Repair of experimental tympanic membrane perforations. *Acta Otolaryngol* 1980;90:332-41.
11. Fina M, Bresnick S, Baird A, Ryan A. Improved healing of tympanic membrane perforations with basic fibroblast growth factor. *Growth Factors* 1991;5:265-72.
12. Mondain M, Saffiedine S, Uziel A. Fibroblast growth factor improves the healing of experimental tympanic membrane perforations. *Acta Otolaryngol* 1991;111:337-41.
13. Vrabec JT, Schwaber MK, Davidson JM, Clymer MA. Evaluation of basic fibroblast growth factor in tympanic membrane repair. *Laryngoscope* 1994;104:1059-64.
14. O'Daniel TG, Petitjean M, Jones SC, et al. Epidermal growth factor binding and action on tympanic membranes. *Ann Otol Rhinol Laryngol* 1990;99:80-4.
15. Kaftan H, Herzog M, Mieke B, Hosemann W. Topical application of transforming growth factor-beta1 in acute traumatic tym-

- panic membrane perforations: an experimental study in rats. *Wound Rep Reg* 2006;14:453–6.
16. Kehrl W, Sonnemann U. Dexpanthenol nasal spray as an effective therapeutic principle for treatment of rhinitis sicca anterior. [Article in German] *Laryngorhinootologie* 1998;77:506–12.
 17. Gouteva I, Shah-Hosseini K, Meiser P. Clinical efficacy of a spray containing hyaluronic acid and dexpanthenol after surgery in the nasal cavity (septoplasty, simple ethmoid sinus surgery, and turbinate surgery). *J Allergy (Cairo)* 2014;2014:635490.
 18. Özel BF, Yasan H, Çiriş M, Doğru H, Çandır Ö. Miringoskleroz gelişimi ve kulak zarı perforasyonu iyileşmesi üzerine farklı ajanların etkileri. *KBB-Forum* 2005;4:123–7.
 19. Gunes Bilgili S, Calka O, Akdeniz N, Bayram I, Metin A. The effects of retinoids on secondary wound healing: biometrical and histopathological study in rats. *J Dermatolog Treat* 2013;24:283–9.
 20. Yardimci I, Karakan T, Resorlu B, et al. The effect of intraurethral dexpanthenol on healing and fibrosis in rats with experimentally induced urethral trauma. *Urology* 2015;85:274.e9–13.

This is an open access article distributed under the terms of the Creative Commons Attribution-NonCommercial-NoDerivs 3.0 Unported (CC BY-NC-ND3.0) Licence (<http://creativecommons.org/licenses/by-nc-nd/3.0/>) which permits unrestricted noncommercial use, distribution, and reproduction in any medium, provided the original work is properly cited.

Please cite this article as: Demirdelen S, İmamoğlu M, Arslan S, Saygın İ. Topical dexpanthenol application improves healing of acute tympanic membrane perforations: an experimental study. *ENT Updates* 2016;6(3):116–120.