

Long-term outcomes of functional surgery for attic cholesteatoma

Erdem Atalay Çetinkaya¹, İbrahim Çukurova², Levent Olgun³, Raci Kabakçı³

¹Department of ENT, Antalya Atatürk State Hospital, Antalya, Turkey

²Department of ENT, Tepecik Training and Research Hospital, İzmir, Turkey

³Department of ENT, Bozyaka Training and Research Hospital, İzmir, Turkey

Abstract

Objective: To evaluate the long-term findings obtained using microscopic approaches to attic cholesteatoma and with respect to the reconstruction materials used in ossiculoplasty.

Methods: The results of these procedures were evaluated in 30 of the patients who subsequently returned for follow-up. One of the surgical techniques among atticotomy + tympanoplasty, intact canal wall tympanoplasty (ICWT) and canal wall-down tympanomastoidectomy (CWDT) was performed. The responses to procedures based on postoperative complaints, otoscopy and audiometry results were evaluated and compared with those pre-treatment.

Results: A comparison of the preoperative and postoperative air-bone differences in 26 (85%) patients showed a hearing gain of 5–35 dB. The largest gain was achieved with ICWT type II surgery. Evaluation of the tympanic membrane by microscopic otoscopy showed various degrees of retraction in 30% of the patients in the open group and approximately 20% of those in the closed group. After a six-year long-term follow-up, 55% of the patients in the open group and 45% of those in the closed group had normal findings.

Conclusion: An adequate exposure allowing full removal of an attic cholesteatoma may require an open technique. Compared to closed techniques, this also allows hearing preservation and ossicular reconstruction. Good results in the reconstruction of the ossicles can be achieved using recently developed biomaterials, assuming that the stapes and manubrium mallei are in good condition.

Keywords: Otitis media, ossiculoplasty, attic, cholesteatom.

Özet: Attik kolesteatom fonksiyonel cerrahisinin uzun dönem sonuçları

Amaç: Çalışmanın amacı, attik kolesteatom cerrahisi ve ossiküloplastisinde kullanılan rekonstrüksiyon malzemeleri ile ilgili cerrahi tekniklerden elde edilen uzun dönem sonuçların değerlendirilmesidir.

Yöntem: Uygulanan prosedürlerin sonuçları, uzun dönem takibi için ulaşılabilen 30 hastada değerlendirildi. Hastalara attikotomi + timpanoplasti, intakt kanal timpanoplasti (ICWT) ve açık kanal timpanomastoidektomi (CWDT) prosedürlerinden biri uygulandı. Ameliyat sonrası şikayetler, otoskopi, odyometri sonuçlarına göre prosedürler değerlendirilip tedavi öncesi ile karşılaştırıldı.

Bulgular: Yirmi altı (%85) hastada preoperatif ve postoperatif hava-kemik yolu farkları karşılaştırıldığında 5–35 dB işitme kazancı görüldü. En büyük kazanç ICWT tip II cerrahi ile elde edildi. Mikroskopik kulak zarı değerlendirilmesinde, açık teknik grubundaki hastaların %30 ve kapalı teknik grubunda olanların yaklaşık %20'sinde değişik derecelerde retraksiyon izlendi. Altı yıllık takipte açık gruptaki hastaların %55 ve kapalı grupta olanların %45'inde normal bulgular mevcuttu.

Sonuç: Attik kolesteatomun tamamen çıkarılması açık teknikler gerektirebilir. Kapalı tekniklerle karşılaştırıldığında, açık teknikte de işitme korunması ve kemikçik rekonstrüksiyonu sağlanabilir. Stapes ve manubrium malleinin iyi durumda olduğu durumlarda yeni geliştirilen biyomalzemeler kullanılarak çok iyi sonuçlar elde edilebilir.

Anahtar sözcükler: Otitis media, ossiküloplastisi, attik, kolesteatom.

Since the first description of atticotomy in 1889, by Küster, numerous successful surgeries for attic cholesteatoma have been conducted.^[1] New and more

functional approaches to the eradication of cholesteatoma have arisen from a better understanding of the possible differences in the biological effects of cholesteatoma in

Correspondence: Erdem Atalay Çetinkaya, MD. Department of ENT, Antalya Atatürk State Hospital, Antalya, Turkey.
e-mail: drerdemcetinkaya@gmail.com

Received: August 2, 2015; **Accepted:** September 1, 2015

Online available at:
www.entupdates.org
doi:10.2399/jmu.2016001001
QR code:



relation to its location, and from novel surgical techniques and reconstruction materials.^[2,3] In this paper, we present the results of a systematic retrospective review that may help to evaluate the findings obtained using microscopic approaches to attic cholesteatoma and with respect to the reconstruction materials used in ossiculoplasty.

Materials and Methods

Between January 1992 and December 1993, 64 patients were operated for attic cholesteatoma at our Ear, Nose and Throat (ENT) Department. The results of these procedures for 30 of the patients who subsequently returned for follow-up in 1998 were evaluated. Data on the surgical technique, postoperative complaints, otoscopy results, whether revision surgery was performed, pure tone audiometry results at 500–1000–2000 Hz, and postoperative long-term air and bone conduction averages were considered. The age range of 14 female (46.6%) and 16 male (57.4%) patients was 8–57 years, with an average age of 25.7 years. Data on the age are presented in Fig. 1. After their admission to the clinic, all patients underwent audiometric testing and evaluation of their complaints. Following a routine ENT examination and microscopic otoscopy in our laboratory, pure tone audiometry was conducted. Six of the patients underwent otoendoscopy using endoscopes with diameters of 4 and 2.7 mm and an angle of 0°. Selected images from the monitor output were recorded.

The cholesteatomas were located at or around the attic in all patients: atticotomy + type I tympanoplasty was performed in 10% of cases, atticotomy + type II tympanoplasty in 6.6%, atticotomy + type III tympanoplasty in 6.6%, intact canal wall tympanoplasty (ICWT) type I in 6.6%, ICWT type II in 3.3%, ICWT type III in 6.6%, canal wall-down tympanomastoidectomy (CWDT) type I in 10%, CWDT type II in 36.3%, and CWDT type III in 13.3%. Data on the procedures are presented in Fig. 2.

Ossiculoplasty was performed in 22 (72.6%) patients, with autologous ossicular material used in 11 (5%) of these patients, artificial ossicular material in 10 (45.4%) patients, and homologous ossicular material in one (4.6%) patient. As tympanic membrane reconstruction material, autologous temporalis muscle fascia was used in 29 patients (95.7%). Data on the ossiculoplasty materials used are presented in Fig. 3.

During postoperative follow-up, the otoscopy findings, postoperative complaints, need for revision surgery, postoperative vs. preoperative audiometry, and audiometric test results were evaluated and compared between the patients.

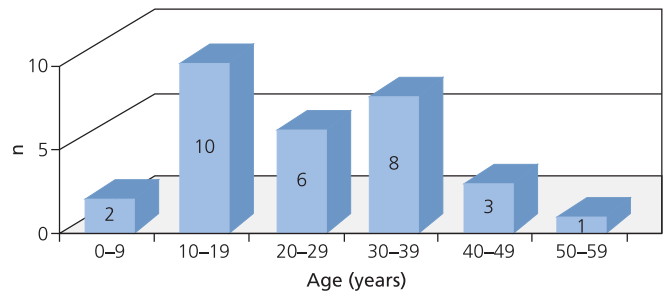


Fig. 1. Data on the age.

Results

Data on the surgical technique, postoperative complaints, otoscopy results, whether revision surgery was performed, pure tone audiometry results at 500–1000–2000 Hz, and postoperative long-term air and bone conduction averages were considered. A comparison of the preoperative and postoperative air-bone differences in 26 (85%) patients showed a hearing gain of 5–35 dB. In three patients, no change was detected and in one patient a 10 dB hearing loss was measured. The average gains depending on the operation type are presented in Fig. 4. The largest gain was achieved with ICWT type II surgery.

The results of 12 patients treated using a closed technique and the 18 patients treated using an open technique

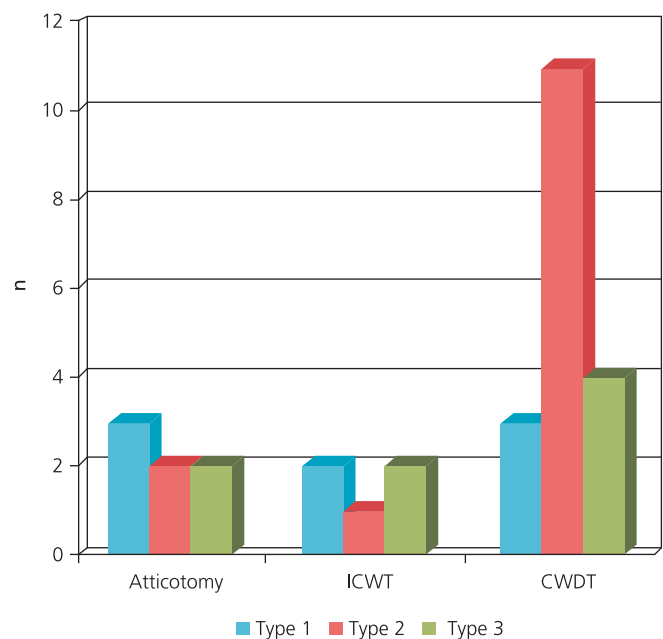


Fig. 2. Data on the procedures.

were analyzed statistically using a Mann-Whitney U test. The difference between the two techniques was not significant ($p=0.249$). Among the 22 patients who underwent ossiculoplasty, the best results in terms of hearing gain were obtained when an incus prosthesis or a partial ossicular replacement prosthesis (PORP) was used.

Evaluation of the tympanic membrane by microscopic otoscopy showed various degrees of retraction in 30% of the patients in the open group and approximately 20% of those in the closed group. The perforation rates were 5.5% (1 patient) and 12% (1 patient), respectively. In addition, tympanosclerosis was detected in 24% of the closed cases (2 patients) and 11% of the open cases (2 patients). After a six-year long-term follow-up, 55% of the patients in the open group and 45% of those in the closed group had normal findings. One patient, operated on with the closed technique, had a recurrence several years postoperatively. Revision surgery was performed using the open technique.

Discussion

The extend pattern of the cholesteatoma is defined by the site of origination. The most common sites are the pars flaccida and the postero-superior of the pars tensa. Retraction pockets especially can cause attic cholesteatoma. Intense mucosal disease and eustachian tube dysfunction may contribute to unfortunate outcomes. The diagnosis of attic cholesteatoma is substantially clinical and treatment is surgical. The fundamental purpose of surgery is to supply a disease-free and functionally better ear.^[1-4]

Since the first description of atticotomy in 1889, numerous successful surgeries for attic cholesteatoma have been conducted. In recent times, sophisticated surgical technology and autologous ossicular materials have facilitated the functional surgery for attic cholesteatoma.^[1,2] In this study, seven patients with cholesteatoma who underwent tympanoplasty using different techniques combined with atticotomy had a hearing gain of approximately 12 dB. Buckingham also advocated standard tympanomastoid operations for cholesteatomas that spread to the eardrum and mastoid, or in which ossicular injury occurred, or in early-stage epitympanic cholesteatoma lateral to the ossicles.^[5] In these patients, atticotomy can maintain a normal or near-normal hearing level. If there is an intact head of malleus and incus body, attic reconstruction is possible and atticotomy could lead to improved hearing. However, postoperative retraction seen in some of patients, a problem that will need to be solved in the future.^[6,7] In our surgical patients, we pre-

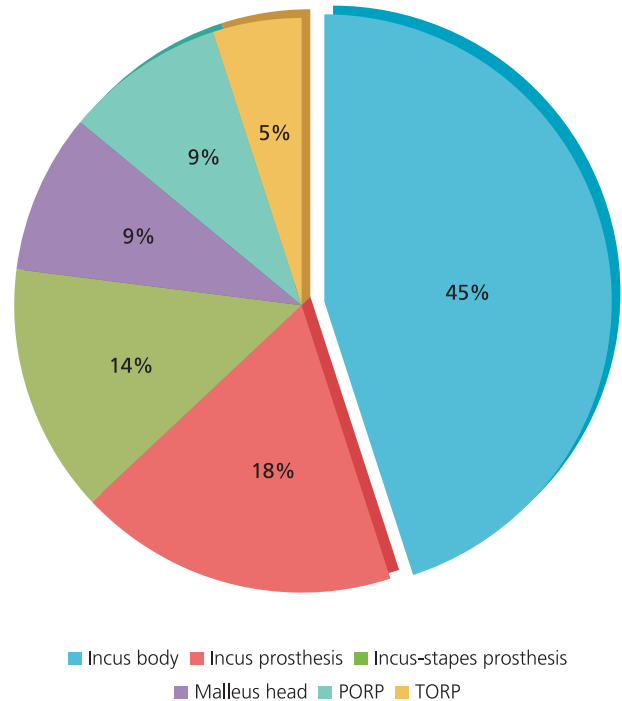


Fig. 3. Data on the used ossiculoplasty materials.

fer to remove the anterior attic bony plate or cog via a transmastoidal approach. In their large series of patients with long-term follow-up in whom anterior tympanotomy operations were not possible. Morimuts et al. found that this strategy reduced the recurrence rate from 17% to 4%.^[8]

The symptoms in attic cholesteatoma are often relatively mild, as hearing loss generally occurs only in the late stage. Therefore, many of these patients will not be referred

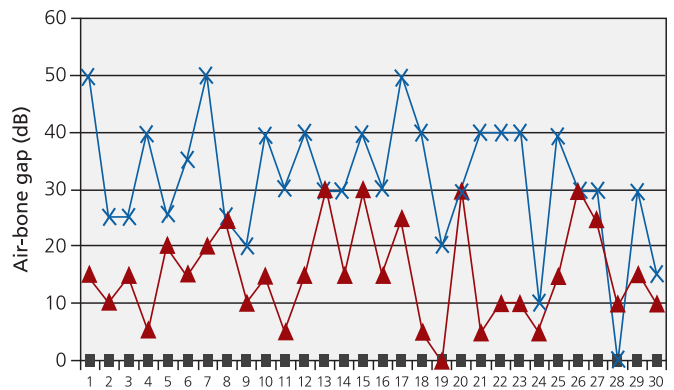


Fig. 4. The average gains are shown, in which the blue line (x) represents preoperative and red line (▲) represents postoperative air-bone gap (dB).

for timely surgery and those with normal hearing or only slight hearing loss will not seek prompt medical attention.^[1,9] Among the patients who underwent CWDT for attic cholesteatoma, the mastoid cavity was closed in 10%, whereas 65% had a small cavity and 25% had a large cavity. In approximately 85%, the cavity remained dry; in more than half of these cases the cavity was self-cleaning whereas in 15% cavity problems developed. In our study, 12% of the patients in the closed group and 5% of those in the open group had perforation. Varying degrees of retraction were detected in 30% and 20%, respectively. The four patients in whom tympanosclerosis developed were monitored; none of them had an effusion of the middle ear. CWDT is an adequate treatment for attic cholesteatoma. The functional outcomes are satisfying. A tympanoplasty can be performed simultaneously. Therefore, in the majority of patients, only a single operation is required. However, CWDT creates an open cavity and modifies the physioanatomy of the middle ear and mastoid. This may cause ear discharge, difficulty in fitting a hearing aid, and potentially a lifetime of outpatient procedures. The ICWT procedure eliminates the need to destroy the middle ear and mastoid, but it is associated with a higher rate of residual cholesteatoma.^[6,10,11] Open procedures are necessary when the disease has destroyed the posterior canal wall or in cases associated with intracranial complications.^[12]

The good hearing outcome is an air-bone gap between 0 and 20 dB for the three frequencies 0.5, 1 and 2 kHz. Tos and Lau found that 36% of patients with a CWDT had an air bone gap ≤ 20 , and 50% of patients with an ICWT had an air bone gap ≤ 20 dB.^[13,14] Our long-term hearing outcomes are comparable to other authors' results.^[14-19] Ossiculoplasty with PORPs had slightly better postoperative hearing than with TORPs. An intact posterior canal wall and a stapes suprastructure are essential to superior hearing outcome.^[20]

Conclusion

In conclusion, there are different surgical procedures for eliminating attic cholesteatoma. Although this study was carried out in 1999, since then surgical techniques that are commonly used for attic cholesteatoma have not changed. An adequate exposure allowing full removal of a cholesteatoma may require an open technique. Compared to closed techniques, this allows hearing preservation and ossicular reconstruction. A successful external ear canal plasty can then be easily performed to obtain a smooth, widened, and open cavity. Good results in the reconstruction of the ossicles can be achieved using recently devel-

oped biomaterials, assuming that the stapes and manubrium mallei are in good condition. However, in patients in whom the upper aspect of the stapes is absent, satisfactory hearing results are still possible by combining biomaterials with autograft cartilage. Middle ear implants represent in selected patients a new remedy to rehabilitate the persistent hearing losses.^[21] The selection of surgical procedure should be individually tailored based on the pre-operative otomicroscopy, hearing and imaging findings.

Conflict of Interest: No conflicts declared.

References

1. Akyıldız N. Kulak hastalıkları ve mikrocerrahisi. Vol. I. Ankara: Bilimsel Tıp Yayınevi; 1998. p. 354-418.
2. Deniz M, Uslu C, Koldaş Ç, Deniz B. Which technique is better for cholesteatoma surgery? *B-ENT* 2015;11:109-15.
3. Minovi A, Venjacob J, Volkenstein S, Dornhoffer J, Dazert S. Functional results after cholesteatoma surgery in an adult population using the retrograde mastoidectomy technique. *Eur Arch Otorhinolaryngol* 2014;271:495-501.
4. Tos M. Removal of attic cholesteatoma in canal wall down mastoidectomy. In: *Manual of middle ear surgery*. Vol. 2. New York, NY: Thieme Medical Publishers, Inc; 1995. p. 241-5.
5. Buckingham R. Atticotomy with presevation of ossicular chain and middle ear intubation as a treatment for small epiympanic cholesteatomas. In: Tos M, editor. *Cholesteatoma and mastoid surgery*. Amsterdam: Kugler & Ghedini Publications 1989; p. 901-3.
6. Tos M. Classic intact canal wall mastoidectomy. In: *Manual of middle ear surgery*. Vol. 1. New York, NY: Thieme Medical Publishers, Inc; 1995. p. 128-130.
7. Ramakrishnan Y, Kotecha A, Bowdler DA. A review of retraction pockets: past, present and future management. *J Laryngol Otol* 2007;121:521-5.
8. Morimitsu T, Tono T, Makino K, Miyayama S, Ushisako Y. Improvement of the surgical technique of anterior tympanoplasty in cholesteatoma. *Rev Laryngol Otol Rhinol (Bord)* 1995;116:369-71.
9. Fiedler T, Boeger D, Buentzel J, et al. Middle ear surgery in Thuringia, Germany: a population-based regional study on epidemiology and outcome. *Otol Neurotol* 2013;34:890-7.
10. Sonkhya N, Mittal P, Sonkhya D. Intact canal wall tympanomastoid surgery: 10 years experience. *Indian J Otolaryngol Head Neck Surg* 2012;64:319-25.
11. Kos MI, Castrillon R, Montandon P, Guyot JP. Anatomic and functional long-term results of canal wall-down mastoidectomy. *Ann Otol Rhinol Laryngol* 2004;113:872-6.
12. Karakaş M, Balıkcı H, Özkul M, Çelebi Ş, Bayram Ö, Bayram AA. Complications of chronic otitis media: a retrospective analysis of 1293 cases. *J Med Updates* 2014;4:43-8.
13. Tos M, Lau T. Hearing after surgery for cholesteatoma using various techniques. *Auris Nasus Larynx* 1989;16:61-73.
14. Tos M, Lau T. Attic cholesteatoma. Recurrence rate related to observation time. *Am J Otol* 1988;9:456-64.

15. Ayache S, Tramier B, Strunski V. Otoendoscopy in cholesteatoma surgery of the middle ear: what benefits can be expected? *Otol Neurotol* 2008;29:1085–90.
16. Alves RD, Cabral Junior F, Fonseca AC, Bento RF. Mastoid obliteration with autologous bone in mastoidectomy canal wall down surgery: a literature overview. *Int Arch Otorhinolaryngol* 2016;20:76–83.
17. Deveze A, Rameh C, Puchol MS, Lafont B, Lavieille JP, Magnan J. Rehabilitation of canal wall down mastoidectomy using a titanium ear canal implant. *Otol Neurotol* 2010;31:220–4.
18. Murphy TP. Hearing results in pediatric patients with chronic otitis media after ossicular reconstruction with partial ossicular replacement prostheses and total ossicular replacement prostheses. *Laryngoscope* 2000;110:536–44.
19. Berçin S, Kutluhan A, Bozdemir K, Yalçiner G, Sari N, Karamese O. Results of revision mastoidectomy. *Acta Otolaryngol* 2009;129:138–41.
20. Lailach S, Zahnert T, Lasurashvili N, Kemper M, Beleites T, Neudert M. Hearing outcome after sequential cholesteatoma surgery. *Eur Arch Otorhinolaryngol* 2015 Sep 3. doi:10.1007/s00405-015-3767-6
21. Ernst A, Todt I, Wagner J. Safety and effectiveness of the Vibrant Soundbridge in treating conductive and mixed hearing loss: a systematic review. *Laryngoscope* 2015 Oct 15. doi:10.1002/lary.25670

This is an open access article distributed under the terms of the Creative Commons Attribution-NonCommercial-NoDerivs 3.0 Unported (CC BY-NC-ND3.0) Licence (<http://creativecommons.org/licenses/by-nc-nd/3.0/>) which permits unrestricted noncommercial use, distribution, and reproduction in any medium, provided the original work is properly cited.

Please cite this article as: Çetinkaya EA, Çukurova İ, Olgun L, Kabakçı R. Long-term outcomes of functional surgery for attic cholesteatoma. *ENT Updates* 2016;6(1):29–33.