

Identification of the immune receptor CD14 in hypertrophic adenoids

Betül Cengiz Peker¹, Mustafa Acar², Murat Şahin³

¹Department of Pathology, Yunus Emre Government Hospital, Eskişehir, Turkey

²Department of Otorhinolaryngology, Yunus Emre Government Hospital, Eskişehir, Turkey

³Department of Radiology, Bolvadin Government Hospital, Afyonkarahisar, Turkey

Abstract

Objective: Tonsils and adenoids are the parts of the Waldeyer's ring. Their basic function is antibody formation which later reacts against a great variety of antigens. Adenoidectomy is the most common operation in small children but the exact reasons of adenoid hypertrophy remain unknown. Therefore, this study aimed at investigating CD14 as surrogate marker of inflammation in children who have to undergo adenoidectomy.

Methods: One hundred pediatric patients with adenoid hypertrophy were included in this study. Intensity of CD14 expression in infiltrating cells was assessed by immunohistochemical methods.

Results: All of the 100 patients underwent adenoidectomies due to chronic adenoid inflammation and hypertrophy. After immunohistochemical analysis, all the specimens were stained as positive (100%) for CD14 expression. Classification of these specimens according to CD14 staining intensity were as follows: 0 as score 0, 36 as score 1, 43 as score 2 and, 21 as score 3. On the other hand, we found statistically significant association between CD14 and age.

Conclusion: In the present study, we showed an increase in the density of CD14 with increasing age.

Keywords: Antigen, CD14, adenoids, adenoidectomy.

Özet: Hipertrofik adenoidlerde immün CD14 reseptörünün tanımlanması

Amaç: Tonsil ve adenoid Waldeyer halkasının bölümleridir. Temel işlevi daha sonra çok çeşitli antijenlerle reaksiyona giren antikor oluşumudur. Küçük çocuklarda adenoidektomi en sık yapılan ameliyat olmasına rağmen adenoid hipertrofinin tam olarak nedenleri hâlâ bilinmemektedir. Bu nedenle bu çalışma adenoidektomi geçirmesi gerekli çocuklarda bir enflamasyon göstergesi belirteci yerine CD14 kullanımını araştırmayı amaçlamıştır.

Yöntem: Bu çalışmaya adenoid hipertrofisi olan yüz çocuk hasta dahil edilmiştir. İnfiltratif hücrelerde CD14 ekspresyonunun yoğunluğu immünohistokimyasal olarak değerlendirilmiştir.

Bulgular: Yüz hastanın tümü adenoidlerin kronik inflamasyonu ve hipertrofileri nedeniyle adenoidektomi ameliyatı geçirmiştir. İmmünohistokimyasal analizden sonra numunelerin tümü CD14 ekspresyonu açısından pozitif (%100) boya tutmuştur. CD14'ün boyanma yoğunluğuna göre bu numunelerin sınıflandırması aşağıdaki gibidir: 0, skor 0; 36, skor 1; 43 skor 2 ve 21 skor 3. Diğer taraftan CD14 düzeyi ile yaş arasında istatistiksel açıdan anlamlı bir ilişki saptadık.

Sonuç: Bu çalışmada yaşla birlikte CD14 dansitesinde artış olduğunu göstermiş olduk.

Anahtar sözcükler: Antijen, CD14, adenoidler, adenoidektomi.

Waldeyer's ring is composed of nasopharyngeal tonsil, paired tubal tonsils, paired palatine tonsils, lingual tonsils and tonsils of the soft palate.^[1] Pharyngeal tonsils consist of adenoids and lateral pharyngeal band. Adenoids are located in the posterosuperior wall of the nasopharynx.^[2] Immunologic functional studies have revealed a variety of immune process-

ing in the adenoids such as toll-like receptor expression.^[3] Inflammation and lymphoid hyperplasia of the adenoids lead to the development of important clinical problems.

Adenoids and tonsils actively participate in the immune defense mechanisms as they express innate immune receptors. The innate immune response is the oldest function of

Correspondence: Mustafa Acar, MD. Department of Otorhinolaryngology, Yunus Emre Government Hospital, Eskişehir, Turkey.
e-mail: drmustafaacar@hotmail.com

Received: October 8, 2015; **Accepted:** November 4, 2015

Online available at:
www.entupdates.org
doi:10.2399/jmu.2015003003
QR code:



the vertebrate immune system which has developed through evolution in order to protect against attack from microorganisms.^[3]

In the literature, a novel mechanism by which mononuclear cells may respond to lipopolysaccharide has been described. CD 14 plays an important role in initiating the responses of leukocytes to lipopolysaccharide (LPS). Lipopolysaccharide is firstly bound by the serum protein LPS binding protein (LBP), and then LPS- LBP complex is recognized by a 55-kD glycoprotein CD14 that is strongly expressed on monocytes and macrophages. LBP and CD14 have two physiological roles, as they act as opsonin and opsonic receptors, respectively, to promote phagocytic uptake of bacteria or LPS-coated particles by macrophages. In addition to its function as an opsonic receptor, CD 14 plays an important role in triggering the responses of leukocytes against lipopolysaccharides.^[4]

The aim of our study is to determine the expression of CD14 as a marker of the innate immunity in hypertrophic adenoids and tonsils extracted from children who underwent adenoidectomies.

Materials and Methods

A total of 100 paraffin-embedded surgical specimens of the patients with adenoid hypertrophies who underwent adenoidectomies at Yunus Emre Government Hospital, between January 2012 and November 2012 were included in the study. All patients underwent adenoidectomies under general anesthesia because of chronic inflammatory hypertrophy of adenoid which had not been responded to previous medical treatments. The diagnosis of adenoid hypertrophy was made on the basis of the medical history and imaging (direct films and computed tomography). Tumor specimens were re-evaluated histologically by the same pathologist after the informed consents were obtained from the family of the patients.

The adenoid tissues were fixed in 10% buffered formalin, routinely processed in automatic tissue processor, and embedded in paraffin blocks. The slides were stained with hematoxylin and eosin and CD14 antibody. Each CD 14 slide was examined using Olympus microscope (Olympus Corp., Tokyo, Japan) with original magnifications of X400 and X100. The staining pattern was classified according to the relative number of positive cells in the specimens. The percentage of CD14 positive cells was semiquantitatively assessed and classified by one observer. Lack of staining with CD14 scored as negative (0). Weak staining was

detected in 0-25% of the total cells and scored as 1 point, while moderate staining was observed in >25-75% of the total cells and scored as 2 points. Finally, strong staining was seen in >75-100% of the cells and scored as 3 points.

All statistical analyses were conducted using SPSS version 20.0 (SPSS Inc., Chicago, IL, USA). The relationship between CD14 expression and other clinical factors (age and sex) was analyzed by the chi-square test and Fisher's exact tests. Data were presented as mean±SD or median (interquartile range, IQR) depending on the distribution unless stated otherwise. For analyses, $p < 0.05$ was considered as the level of significance.

Results

A total of 100 patients underwent adenoidectomy surgery due to chronic adenoid inflammation and hypertrophy. The median age of the patients was 5.96 ± 1.85 (range: 3 to 10) years.

On nasopharyngeal examination, the lymphoid mass appeared more or less like a cauliflower in all children. On histopathological examination, the presence of numerous lymph follicles with prominent germinal centers was the major finding in the adenoids removed from children (Fig. 1). Within the epithelium of adenoid, a population of dendritic mononuclear cells were identified and, follicular dendritic cells were CD14 positive (Fig. 2).

After immunohistochemical analysis, all the specimens were stained as positive (100%) for CD14 expression. Classification of these specimens according to CD14 staining intensity were as follows: 0 as score 0, 36 as score 1, 43 as score 2 and, 21 as score 3. On the other hand, we found statistically significant association between CD14 and age. CD14 staining intensity increased with aging ($p=0.048$).

Discussion

There is very little lymphoid tissue in the nasopharynx of infants and humans are born without substantial adenoids. The mass of lymphoid tissue called adenoids starts to get sizable during the first year of life.^[5,6] Lymphoid tissue connected with mucosa, forming Waldeyer's ring in the nasopharynx, constitutes the first barrier and area of contact for antigens entering the body. The lymphatic tissue should be overactive in filtering out infectious agents in the upper respiratory tract, so it can lead to an increase in lymphoid and epithelial cell size, which results with adenoidal hypertrophy.

Numerous adverse effects of enlarged adenoids have been described in the literature and rationales for surgical removal have been given. The conclusions are controversial. Chronic nasal obstruction due to increased adenoidal size is reported to be associated with obstructive sleep apnea, Eustachian tube dysfunction, otitis media, and abnormal facial growth.^[7,8] Adenoidal hyperplasia may lead to nasal obstruction, which is likely secondary to an absolute increase in adenoid size rather than a relatively smaller nasopharynx.^[9] Therefore, adenoid hypertrophy is a major concern for parents. In our study, all the patients had chronic inflammation and adenoid hypertrophy. Despite medical treatment, if patients suffer from frequent infections, otolaryngologist decides to perform adenoidectomy.

Adenoidectomy and tonsillectomy are among the most frequently performed childhood operations with indications of recurrent infection or obstruction.^[10,11] However, randomized studies demonstrated the effectiveness of intranasal corticosteroids in children with adenoid hypertrophy.^[12,13] Demain and Goetz reported for the first time the use of intranasal corticosteroids in the treatment of adenoid hypertrophy.^[12] After that, much work has been done in the literature. The effectiveness of the steroids was observed in these studies. Therefore adenoidectomy indications still remain a matter of debate.^[11,14] We wonder whether the actual mechanism of the adenoid hypertrophy is bacterial antigenic stimulation or not. The size of adenoids demonstrates variations among children. In the lit-

erature, several authors have tried to explain why and how a modification in the balance between the local immunological function of the host and the infectious agents would lead to a clinical process characterized by recurrent inflammatory events.^[15,16] We looked for the variations in immunological function in children with adenoid. CD14 is expressed in abundance on the surface of mature monocytes and in trace amounts on granulocytes. Lipopolysaccharide binding protein and CD14 serve two physiological roles. These proteins act as opsonin and opsonic receptor, respectively, to promote the phagocytic uptake of bacteria or lipopolysaccharide-coated particles by macrophages.^[17] They also dramatically enhance the ability of mononuclear cells to synthesize TNF in response to endotoxins. In the present study, we specifically chose to determine CD14 expression due to the importance of this receptor in the innate immune response. It is currently accepted that adenoidal hypertrophy is caused by the antigen-stimulated increased activity of lymphocytes.^[3,4] Fujiyoshi et al. have demonstrated that hypertrophied adenoidal tissue showed evidence of immunologic activation and chronic inflammation in patients who had undergone adenoidectomy surgery.^[18] The enhanced expressions of CD14 cells in submucosal, lymph follicles, and interfollicular layers of adenoids may be an important factor for the development and persistence of adenoids.^[3] Ben-Yaakov et al. reported that hypertrophic adenoids and tonsils from children with obstructive sleep apnea are prominent sites of innate defense, with resultant overex-

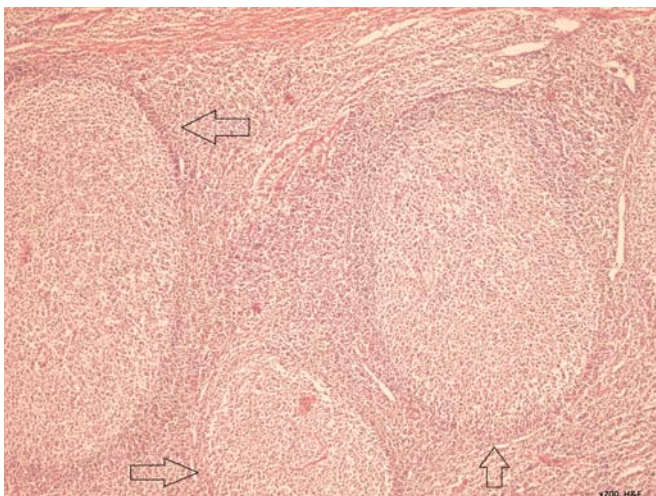


Fig. 1. Histopathological view of adenoid tissue, showing prominent hyperplasia in the germinal centers (arrows) (Haematoxylin and eosin stain, $\times 200$).

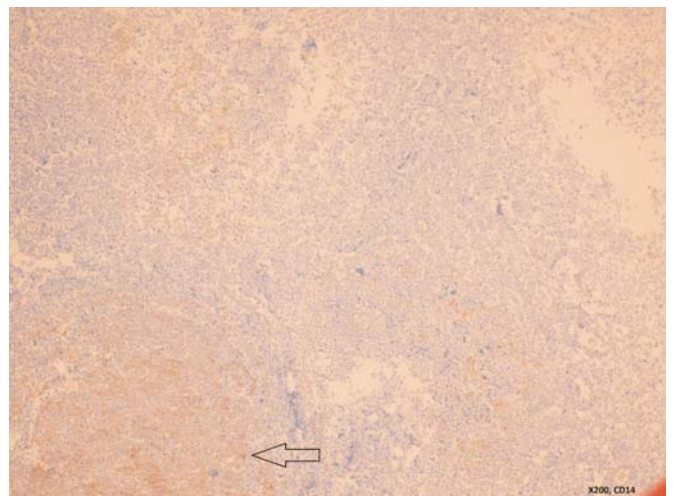


Fig. 2. Positive CD14 staining (arrow) in adenoid tissue ($\times 200$).

pression of CD14.^[3] Given the constant exposure of tonsillar epithelium to bacteria, expression of CD14 in response to exposure to bacterial constituents is triggered.^[3,4] However, many infectious pathogens are encountered during childhood. We found higher CD14 densities in patients with frequent exposures. This is the reason why young age adenoid hypertrophy brings to mind another cause of bacterial stimuli.

Currently, several pitfalls of adenoidectomy (i.e. alteration of the immunological system, postoperative bleeding, and recurrence of adenoids) are object of criticism. In this study, we saw an increase in the density of CD14 with increasing age. Bacterial antigenic stimulation at a relatively earlier age indicates that there is no strong relationship between adenoid hypertrophy, and age. It is difficult for parents, to decide on adenoidectomy for their small children. Children with adenoidal hypertrophy that is not associated with infection should be considered for steroid treatment before surgery is planned. However, larger case series and molecular investigations are needed to clarify this issue.

Conflict of Interest: No conflicts declared.

References

- Perry M, Whyte A. Immunology of the tonsils. *Immunol Today* 1998;19:414–21.
- Yildirim N, Sahan M, Karslioğlu Y. Adenoid hypertrophy in adults: clinical and morphological characteristics. *J Int Med Res* 2008;36:157–62.
- Ben-Yaakov A, Maly B, Abu-Ita R, Elidan J, Gross M. Identification and immunolocalization of the innate immune receptor CD14 in hypertrophic adenoids and tonsils. *Immunol Invest* 2011;40:150–9.
- Wright SD, Ramos RA, Hermanowski-Vosatka A, Rockwell P, Detmers PA. Activation of the adhesive capacity of CR3 on neutrophils by endotoxin: dependence on lipopolysaccharide binding protein and CD14. *J Exp Med* 1991;173:1281–6.
- Brodsky L. Modern assessment of tonsils and adenoids. *Pediatr Clin North Am* 1989;36:1551–69.
- Wang DY, Bernheim N, Kaufman L, Clement P. Assessment of adenoid size in children by fiberoptic examination. *Clin Otolaryngol Allied Sci* 1997;22:172–7.
- Deutsch ES. Tonsillectomy and adenoidectomy. *Pediatr Otolaryngol* 1996;43:1319–38.
- Richardson, MA. Sore throat, tonsillitis, and adenoiditis. *Med Clin North Am* 1999;83:75–83.
- Brodsky L, Koch J. Anatomic correlates of normal and diseased adenoids in children. *Laryngol* 1992;102:1268–74.
- Taylan I, Ozcan I, Mumcuoğlu I, et al. Comparison of the surface and core bacteria in tonsillar and adenoid tissue with beta-lactamase production. *Indian J Otolaryngol Head Neck Surg* 2011;63:223–8.
- Wiatrak BJ, Woolley AL. Pharyngitis and adenotonsillar disease. In: Cummings CW, Frederickson JM, Harker LA, Krause CJ, Schüller DE, editors. *Otolaryngology – head and neck surgery*. 2nd ed. St. Louis: Mosby Year Book; 1993. p. 2795–801.
- Demain JG, Goetz DW. Pediatric adenoidal hypertrophy and nasal airway obstruction: reduction with aqueous nasal beclomethasone. *Pediatrics* 1995;95:355–64.
- Criscuoli G, D'Amora S, Ripa G, et al. Frequency of surgery among children who have adenotonsillar hypertrophy and improve after treatment with nasal beclomethasone. *Pediatrics* 2003;111:e236–8.
- Maw AR. Chronic otitis media with effusion (glue ear) and adenotonsillectomy: prospective randomised controlled study. *Br Med J (Clin Res Ed)* 1983;287(6405):1586–8.
- Bernstein JM, Sendor S, Wactawski-Wende J. Antigen-presenting cells in the nasopharyngeal tonsil. A quantitative immunohistochemical study. *Adv Otorhinolaryngol* 1992;47:80–90.
- Flanagan JG, Rabbits TH. Arrangement of human immunoglobulin heavy chain constant region genes implies evolutionary duplication of a segment containing gamma, epsilon and alpha genes. *Nature* 1982;300:709–13.
- Wright SD, Tobias PS, Ulevitch RJ, Ramos RA. Lipopolysaccharide (LPS) binding protein opsonizes LPS-bearing particles for recognition by a novel receptor on macrophages. *J Exp Med* 1989;170:1231–41.
- Fujiyoshi T, Watanabe T, Ichimiya I, Mogi G. Functional architecture of the nasopharyngeal tonsil. *Am J Otolaryngol* 1989;10:124–31.

This is an open access article distributed under the terms of the Creative Commons Attribution-NonCommercial-NoDerivs 3.0 Unported (CC BY-NC-ND3.0) Licence (<http://creativecommons.org/licenses/by-nc-nd/3.0/>) which permits unrestricted noncommercial use, distribution, and reproduction in any medium, provided the original work is properly cited.

Please cite this article as: Cengiz Peker B, Acar M, Şahin M. Identification of the immune receptor CD14 in hypertrophic adenoids. *ENT Updates* 2015;5(3):93–96.