

Comparison of cold knife tonsillectomy versus thermal welding tonsillectomy in adults: a prospective trial

Deniz Hancı¹, Hüseyin Altun²

¹Department of Otorhinolaryngology, Yunus Emre Hospital, Istanbul, Turkey

²Department of Otorhinolaryngology, Okmeydanı Training and Research Hospital, Istanbul, Turkey

Abstract

Objective: The aim of this prospective study was to compare the duration and the postoperative complaints of the patients who had tonsillectomies with cold knife vs thermal welding.

Methods: Thirty-one adults undergoing tonsillectomy were included. Traditional tonsillectomy was implemented in one tonsil, and thermal welding tonsillectomy (TWT) was implemented in other tonsil of the same patient. Duration of the operation, amounts of blood loss and morbidity (postoperative pain) were recorded.

Results: Degree of pain, as assessed by Visual Analogue Scale, within the 1st postoperative day was not different between the two groups. Sensation of pain in 2nd–14th days were significantly lower in TWT group than in traditional tonsillectomy group. Although sensation of throat swelling and difficulty in eating tended to be lower in TWT group than in traditional tonsillectomy group, difference was not statistically significant. Although degree of ear ache on TWT side tended to be lower than traditional tonsillectomy side, difference was not statistically significant. In terms of postoperative hemorrhage, there was no difference between two tonsillectomy techniques. Duration of operation was significantly lower in TWT group than in traditional tonsillectomy group.

Conclusion: TWT results in decreased postoperative pain and significantly shortened operation time compared to the traditional tonsillectomy. Therefore, we suggest that TWT is a quite effective in tonsillectomy procedure.

Keywords: Tonsillectomy, thermal welding tonsillectomy, cold knife tonsillectomy, complication, pain, operation time.

Özet: Erişkinde soğuk bıçak tonsillektomi ve termal *welding* tonsillektominin karşılaştırılması: prospektif çalışma

Amaç: Bu prospektif çalışmanın amacı soğuk bıçak ve termal *welding* ile tonsillektomi olmuş hastalarda ameliyat süresi ve postoperatif yakınmaları karşılaştırmaktır.

Yöntem: Tonsillektomi olmuş 31 erişkin çalışmaya dahil edilmiştir. Hastanın bir bademciğine geleneksel tonsillektomi aynı hastanın diğer bademciğine termal *welding* tonsillektomi (TWT) uygulanmıştır. Ameliyat süresi, kaybedilen kan miktarı ve morbidite (postoperatif ağrı) kaydedilmiştir.

Bulgular: Görsel Analog Skalasıyla değerlendirildiği gibi iki grup arasında birinci postoperatif gün farklı değildi. Geleneksel tonsillektomi grubuna göre TWT grubunda ağrı duyusu 2.–14. günlerde anlamlı derecede daha düşüktü. Boğazda şişme ve yemek yemede zorluk duyusu geleneksel gruba göre TWT grubunda daha az olma eğiliminde olmasına rağmen farklılık istatistiksel açıdan anlamlı değildi. Postoperatif kanama açısından iki tonsillektomi tekniği açısından farklılık yoktu. Geleneksel tonsillektomi grubuna göre TWT grubunda ameliyat süresi daha kısa idi.

Sonuç: Geleneksel tonsillektomiyle karşılaştırıldığında TWT postoperatif ağrıda azalma ve ameliyat süresinde anlamlı derecede kısalmayla sonuçlanmaktadır. Bu nedenle TWT'nin tonsillektomi işlemi olarak oldukça etkili olduğunu düşünmekteyiz.

Anahtar sözcükler: Tonsillektomi, termal *welding* tonsillektomi, soğuk bıçak tonsillektomi, komplikasyon, ağrı, ameliyat süresi.

Tonsillectomy is one of the procedures of otorhinolaryngologic surgery that has been used most frequently. A lot of technical definitions were made for tonsillectomy

including blunt dissection and laser tonsillectomy.^[1–3] The common objective in all of these techniques is to perform a fast and bloodless operation and to minimize the postop-

Correspondence: Deniz Hancı, MD. Department of Otorhinolaryngology, Yunus Emre Hospital, Istanbul, Turkey.
e-mail: dhanci007@hotmail.com

Received: April 24, 2015; **Accepted:** June 26, 2015

Online available at:
www.entupdates.org
doi:10.2399/jmu.2015002003
QR code:



erative morbidity. In recent years, “thermal welding” was introduced and promoted as an effective tonsillectomy technique, in which a new device grasps and divides the tissue simultaneously. The “Thermal Welding Tonsillectomy” (TWT) equipment consists of the following items; one forceps, double-controlled foot pedal and a universal power supply. The heater end (point) is activated by means of a reusable foot pedal and consequently the protein molecules inside the tissue are denatured. The heater end cannot be activated unless the tips of the forceps came in close contact. Therefore, in order to excise the tissue, the surgeon must hold and squeeze the tissue between the forceps. During this process, the protein molecules in the tissue become denatured and adhere tightly to one another. The amount of heat produced between the two tips of the instrument is mostly effective on the epicenter of the tissue, and therefore the peripheral tissues are only minimally affected from the heat during the procedure.^[4]

In this study, cold knife tonsillectomy was compared with TWT in terms of the operation time, intraoperative blood loss, postoperative hemorrhage and morbidity, namely postoperative pain, in adults. To our knowledge, this is the first study in the literature in which the two techniques were implemented in the same patient in the pediatric age group.

Materials and Methods

Study design

This study was performed in accordance with the Declaration of Helsinki and the local ethics committee approved the study. Written informed consent was obtained from all of the patients. The study had a prospective design. Thirty-one adult patients undergoing tonsillectomy were enrolled. The indications of tonsillectomy were chronic tonsillitis and obstructive sleep apnea. None of the patients had a systematic disease. All operations were performed by the same surgeon at Rose position under general anesthesia. Traditional tonsillectomy was performed on one whereas TWT on the other tonsil of the same patient. Traditional tonsillectomy was performed by means of sharp dissection. Hemostasis was maintained by bipolar cautery. In TWT, the tonsil was dissected away from its fossa beginning from the upper “pole” and proceeding towards the bottom pole of the tonsil without any mucosal incision. In order to control intraoperative bleeding, either a TW forceps or a bipolar cautery was used.

Oral intake was allowed after the first 4 hours of the tonsillectomy operation, whereas solid food intake was allowed after the tenth postoperative day. Postoperatively, all patients were recommended to use antibiotics and analgesics. For each patient, operation time was noted and the amounts of intraoperative and postoperative blood loss were determined. All patients were asked to fill out a questionnaire in order to determine whether they had postoperative problems in eating and/or drinking and in mouth movements. Besides, other possible complications were noted. In addition, the normal diet cycle time, which indicated the time to start a normal diet without pain and without the need for analgesia was noted.

Outcome parameters

Pain was assessed via “Visual Analogue Scale” (VAS) for each tonsillectomy side. All patients were asked to report any kind of postoperative painful symptoms from the very immediate postoperative period. Results of VAS were evaluated on a 100 mm vertical line. Those without any painful symptom were assigned “0” and those with a lot of symptoms “100” points. All patients completed the pain assessment via VAS within the first 14 days after the tonsillectomy procedure. Other symptoms including sensation of swelling, difficulty in drinking, and eating and ear ache were also assessed by VAS for each side.

Between the 7th–14th postoperative days, tonsillar fossa was examined for the presence of edema and meanwhile the healing rate was noted. If the edema at the one side was less or more than than the other side, it was evaluated with “0” or “1” point respectively.

Statistical analysis

Statistical analysis was performed with SPSS software (Statistical Package for Social Sciences, version 10.0; SPSS Inc., Chicago, IL, USA). Data were expressed as mean (minimum-maximum) where appropriate. Results were considered statistically significant if the 2-tailed P value was <0.05. Normality of the data was evaluated by the Kolmogorov–Smirnov test. Comparisons of the groups were assessed by means of the Student t test for normally, and with Mann–Whitney U test for non-normally distributed continuous variables.

Results

Overall, 31 patients were enrolled in the study with a mean age of 34 years, and male/female ratio of 15/16. None of the patients suffered from hemorrhage, peritonsillary or uvular

edema postoperatively. Fig. 1 demonstrates the comparative surge of pain, as assessed by VAS scores of the patients who had undergone traditional tonsillectomy versus TWT during successive postoperative days. When the degree of pain within the 1st postoperative day was compared between the two groups, the difference was not statistically significant ($p > 0.05$). However, the sensation of pain between the 2nd and 14th days, as assessed by VAS scores, were significantly lower in the TWT group than in the traditional tonsillectomy group ($p < 0.001$). Although the sensation of throat swelling tended to be lower in the TWT group than in the traditional tonsillectomy group, the difference was not statistically significant (Fig. 2). Similarly, difficulty in eating and drinking were not significantly different between the two groups (Figs. 3 and 4). Although the degree of ear ache on the TWT side tended to be lower than the traditional tonsillectomy side, the difference was not statistically significant (Fig. 5).

In terms of postoperative hemorrhage, there was no difference between the two tonsillectomy techniques. However, the duration of the operation was significantly lower in the TWT group than in the traditional tonsillectomy group [8.2 min (6–10 min) vs 14.3 min (12–16 min), $p < 0.001$] (Fig. 6).

Discussion

In this study, we demonstrated that sensation of pain in the 2nd–14th postoperative days of tonsillectomy, as assessed by VAS scores, were significantly lower in the TWT group than in the traditional tonsillectomy group ($p < 0.001$). We have also shown that TWT technique resulted in signifi-

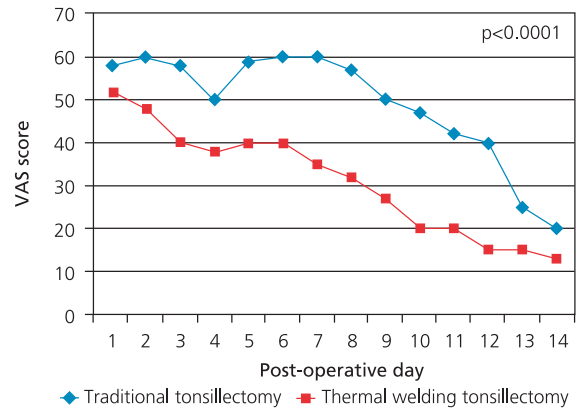


Fig. 1. Comparative surge of pain, as assessed by VAS scores, of patients who had undergone traditional tonsillectomy versus TWT during successive postoperative days.

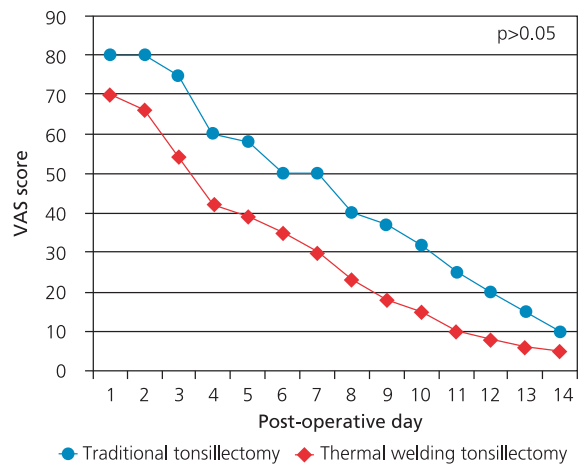


Fig. 2. The VAS scores estimated for the sensation of throat swelling in the TWT group and in the traditional tonsillectomy group during postoperative days.

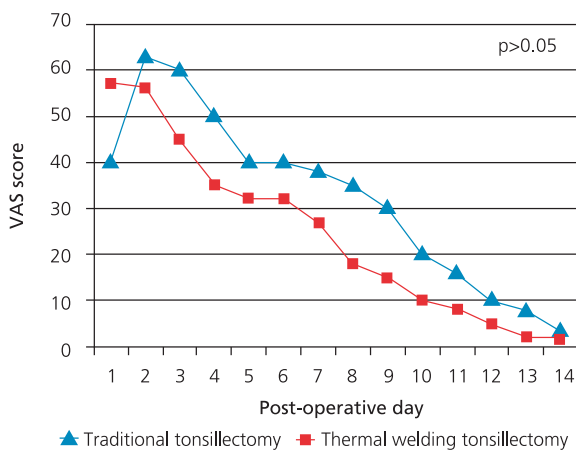


Fig. 3. The VAS score of difficulty in eating during postoperative days.

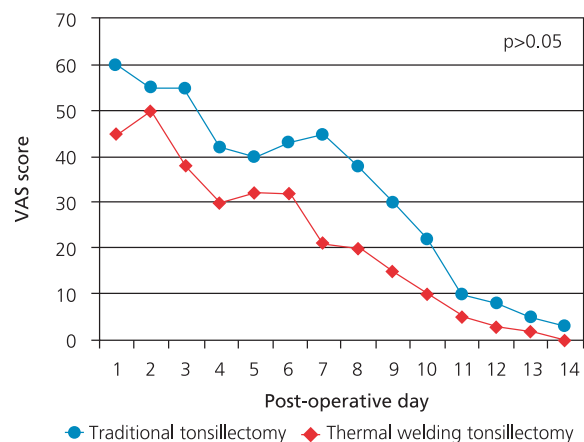


Fig. 4. The VAS score of difficulty in drinking during postoperative days.

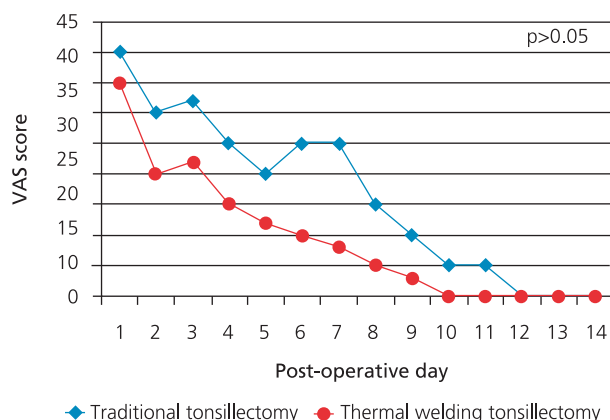


Fig. 5. The VAS score of the degree of ear ache on the TWT and also the traditional tonsillectomy sides during postoperative days.

cantly shorter operation times when compared to the traditional tonsillectomy technique ($p < 0.001$).

Tonsillectomy is the most frequently applied surgical procedure in adults.^[5] Various surgical tonsillectomy techniques were introduced including traditional dissection, electrocautery, cryosurgery, “coblation”, laser surgery, monopolar-bipolar dissection and thermal welding.^[6] Each method has its own advantages and disadvantages. The most important targets of the new tonsillectomy techniques in common are to shorten the time of surgery, to decrease bleeding and to augment patient comfort.^[7-10] Thermal welding tonsillectomy technique differs from other electro-surgical techniques in that it dissects and coagulates veins and tissue by using direct energy and pressure. In other words, it applies direct thermal energy instead of changing the type of energy.^[11] In this technique, the dissected tissue suffers minimal damage, and therefore the TWT is suggested to be the most suitable procedure for tonsillectomy.^[12] There are many reports in the literature in which the different tonsillectomy techniques were compared.^[13] Nevertheless, the comparative data for TWT techniques is relatively scarce.

In the study by Karatzias et al., it was demonstrated that with TWT method, surgical time was shorter, intraoperative bleeding was minimal and the patients returned to their normal diet in a shorter time after the operation when compared to bipolar tonsillectomy.^[9] In another study by Sezen et al., TWT was compared with traditional tonsillectomy.^[11] They reported that in patients, who had undergone the TWT operation, lower amount of bleeding and short-

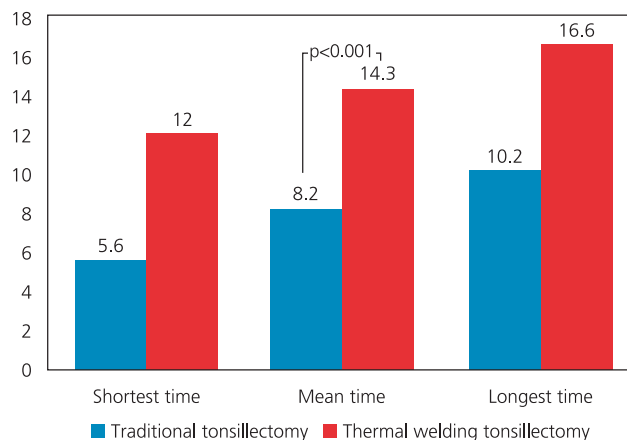


Fig. 6. Operation times in the TWT and the traditional tonsillectomy groups.

er operation times were found when compared to patients who had undergone traditional tonsillectomy procedure. Furthermore, they showed that the postoperative pain was not severe in the TWT procedure when compared to traditional tonsillectomy. However, this study was carried out in a patient population aged 3–28 years and the two different techniques were used in different patients. We think that this study design bares some disadvantages such that some patient-related factors may inevitably influence the results and data interpretation. On the other hand, since traditional and TWT techniques techniques were applied on the same patient, our study design has the advantage of eliminating patient-related factors (i.e. bleeding time, and pain threshold) effective on the comparisons between these two techniques. Additionally, the study by Sezen et al. enrolled both pediatric and adult patients. However, in our study, we included only adult patients (median age: 28 years; range: 18 to 55 years), therefore we think that our results may be extrapolated to the adult patient population more safely.

Lee et al. stated that there was no difference between the cold and hot dissection methods as for rates of secondary hemorrhage.^[12] On the other hand, Stavroulaki et al. indicated that the TWT decreased the postoperative morbidity significantly, and the authors defined TWT as a safe and secure technique for tonsillectomy.^[10] Similarly, Weinstock et al. demonstrated that the healing time after TWT was rather faster when compared to cold dissection.^[11] Conflicting with these results, Yaşar et al. carried out two studies comparing TWT and cold dissection in both adults

and children.^[13,14] They failed to demonstrate a significant difference in terms of patient comfort and operative complications in patients who had undergone TWT or cold dissection. In summary, the great majority of the data in the literature favor TWT as a reliable and safe tonsillectomy technique. Our results are in favor of TWT in terms of operation times, and postoperative pain, which further support the cumulative data in the literature.

The study with children is not without limitations. Firstly and most importantly, use of VAS for the pediatric patient population may be problematic. For that reason, our study has included only adult patients.

Conclusion

Thermal welding tonsillectomy results in decreased postoperative pain and significantly shortened operation time compared to the traditional tonsillectomy. Therefore, we advocate that TWT is quite effective as a tonsillectomy procedure.

Conflict of Interest: No conflicts declared.

References

1. Younis RT, Lazar RH. History and current practice of tonsillectomy. *Laryngoscope* 2012;112(8 Pt 2 Suppl 100):3–5.
2. Timms MS, Temple RH. Coblation tonsillectomy: a double blind randomized controlled study. *J Laryngol Otol* 2002;116:450–2.
3. Belloso A, Chidambaram A, Morar P, Timms MS. Coblation tonsillectomy versus dissection tonsillectomy: postoperative hemorrhage. *Laryngoscope* 2003;113:2010–3.
4. Treat MR. A new thermal device for sealing and dividing blood vessels [accessed 2015 March 21]. Available from: <http://www.starioninstruments.com/PDFs/Treat.pdf>.
5. Curtin JM. The history of tonsil and adenoid surgery. *Otolaryngol Clin North Am* 1987;20:415–9.
6. Kirazli T, Bilgen C, Midilli R, Ogut F, Uyar M, Kedek A. Bipolar electrodissection tonsillectomy in children. *Eur Arch Otorhinolaryngol* 2005;262:716–8.
7. Silveira H, Soares JS, Lima HA. Tonsillectomy: cold dissection versus bipolar electrodissection. *Int J Pediatr Otorhinolaryngol* 2003;67:345–51.
8. Karatzias GT, Lachanas VA, Papouliakos SM, Sandris VG. Tonsillectomy using the thermal welding system. *ORL J Otorhinolaryngol Relat Spec* 2005;67:225–9.
9. Karatzias GT, Lachanas VA, Sandris VG. Thermal welding versus bipolar tonsillectomy: a comparative study. *Otolaryngol Head Neck Surg* 2006;134:975–8.
10. Stavroulaki P, Skoulakis C, Theos E, Kokalis N, Valagianis D. Thermal welding versus cold dissection tonsillectomy: a prospective, randomized, single-blind study in adult patients. *Ann Otol Rhinol Laryngol* 2007;116:565–70.
11. Sezen O, Kaytancı H, Kubilay U, Coşkuner T, Unver S. Comparison between tonsillectomy with thermal welding and the traditional cold tonsillectomy technique. *ANZ J Surg* 2008;78:1014–8.
12. Lee MS, Montague ML, Hussain SS. Post-tonsillectomy hemorrhage: cold versus hot dissection. *Otolaryngol Head Neck Surg* 2004;131:833–6.
13. Yasar H, Ozkul H, Verim A. Comparison of the thermal welding technique and cold dissection for pediatric tonsillectomy. *Balkan Med J* 2009;26:326–30.
14. Yasar H, Ozkul H. Thermal welding technique versus cold dissection for adult tonsillectomy. *B-ENT* 2010;6:251–4.

This is an open access article distributed under the terms of the Creative Commons Attribution-NonCommercial-NoDerivs 3.0 Unported (CC BY-NC-ND3.0) Licence (<http://creativecommons.org/licenses/by-nc-nd/3.0/>) which permits unrestricted noncommercial use, distribution, and reproduction in any medium, provided the original work is properly cited.

Please cite this article as: Hancı D, Altun H. Comparison of cold knife tonsillectomy versus thermal welding tonsillectomy in adults: a prospective trial. *ENT Updates* 2015;5(2):63–67.