

Unilateral nasal pathologies: clinical presentation and management

Cüneyt Kucur¹, Fatih Oğhan¹, İsa Özbay¹, Onur Erdoğan¹, Şermin Tok², Bekir Şanal²,
Mehmet Korkmaz², Nadir Yıldırım¹

¹Department of Otorhinolaryngology, Faculty of Medicine, Dumlupınar University, Kütahya, Turkey

²Department of Radiology, Faculty of Medicine, Dumlupınar University, Kütahya, Turkey

Abstract

Objective: To evaluate the histopathological examination results, frequency of lesions and associated symptoms in patients with established unilateral nasal pathology.

Methods: Medical records of 73 patients with unilateral nasal lesions who undergone histopathological examination were analyzed retrospectively. Clinical presentation, examination and radiological findings, treatment and follow-up process of the patients were evaluated.

Results: Neoplastic (n=16) and non-neoplastic (n=57) pathologies were detected in 73 patients. Non-neoplastic lesions consisted of inflammatory polyps (n=16), chronic sinusitis (n=11), anthrocoanal polyps (n=6) which were the most striking unilateral nasal pathologies. Neoplastic group (n=16) comprised of 2 malignant and 14 benign cases which were classified as adenocarcinoma (n=1), adenoid cystic carcinoma (n=1), inverted papilloma (n=8), hemangioendothelioma (n=1), capillary hemangioma (n=1), fibrous dysplasia (n=1), osteoma (n=1) and pyogenic granuloma (n=2). The most frequently observed symptom was unilateral nasal obstruction. Especially in cases with neoplasms, the frequency of epistaxis increased significantly (p<0.05).

Conclusion: In cases with unilateral sinonasal symptoms, neoplasias should be kept in mind. A detailed anamnesis, attentive endoscopic examination and appropriate radiological imaging modalities in suspected cases and recurrent biopsies in case of need can reveal underlying pathologies.

Keywords: Nasal pathologies, unilateral, nasal obstruction.

Özet: Tek taraflı nazal patolojilerin klinik prezentasyonu ve yönetimi

Amaç: Tek taraflı nazal patoloji tespit edilmiş olan hastalarda, patolojik inceleme sonuçları ile lezyonların sıklığı ve eşlik eden semptomların değerlendirilmesi.

Yöntem: Tek taraflı nazal lezyonu mevcut olan ve patolojik incelemesi yapılmış olan 73 hastanın kayıtları retrospektif olarak incelendi. Hastaların klinik prezentasyonu, muayene ve radyolojik görüntüleme bulguları, tedavi ve takip süreci değerlendirildi.

Bulgular: Bulguları incelenen 73 hastanın; 16'sında neoplastik, 57'sinde neoplastik olmayan patoloji tespit edildi. Neoplastik olmayan lezyonlara baktığımızda; 16 olguda inflamatuvar polip, 11 olguda kronik sinüzit, 6 olguda antrokoanal polip, en çok göze çarpan nedenlerdi. Neoplastik grubu ise 2'si malign, 14'ü benign 16 olgu oluşturmaktaydı. Bu olgular; 1 adenokarsinom, 1 adenoid kistik karsinom, 8 inverted papillom, 1 hemanjiendothelyoma, 1 kapiller hemanjiom, 1 fibröz displazi, 1 osteom, 2 pyojenik granülomdan oluşmaktaydı. En sık gözlenen semptom, tek taraflı burun tıkanıklığıydı. Özellikle neoplazm olgularında burun kanaması sıklığı anlamlı olarak artmıştı (p<0.05).

Sonuç: Tek taraflı sinonazal semptomları olan olgularda neoplazmlar akılda tutulmalıdır. Detaylı bir anamnez, dikkatli bir endoskopik muayene ve şüpheli olgularda uygun radyolojik görüntüleme yöntemleri ile gerekirse tekrarlayan biyopsiler de yapılarak altta yatan patolojiler anlaşılabilir.

Anahtar sözcükler: Nazal patolojiler, tek taraflı, burun tıkanıklığı.

Nasal obstruction, discharge and bleeding, pain radiating to face and eyes are the most frequent causes of presentation to the otorhinolaryngology clinics. However, unilat-

eral complaints should alert the physician to the possibility of the underlying neoplastic mass lesion. Patients with such complaints should be evaluated with a meticulously

Correspondence: Cüneyt Kucur, MD. Department of Otolaryngology, Faculty of Medicine, Dumlupınar University, Kütahya, Turkey.
e-mail: ckucur@gmail.com

Received: November 11, 2014; **Accepted:** January 7, 2015

Online available at:
www.entupdates.org
doi:10.2399/jmu.2015001007
QR code:



endoscopic examination, and in case of suspicion, imaging modalities should be used so as to make an accurate differential diagnosis. All unilateral mass lesions should be evaluated as malignant lesion, unless proved otherwise.^[1]

Sinonasal masses can be classified as malignant, benign tumors and non-neoplastic lesions. The most frequently seen intranasally located malignant and benign tumors are squamous cell carcinomas and nasal polyps respectively.^[2] In differential diagnosis, retention cyst, mucocele, inverted papilloma, benign and malignant tumors of the minor salivary glands, hemangioma, neurogenic tumors, epidermoid carcinoma and lymphoma should be contemplated.^[3]

Although intranasal masses can be most frequently detected using anterior rhinoscopic and endoscopic examination methods, routine paranasal sinus tomograms should be obtained so as to determine the origin and extension of the mass lesions and for the purpose of planning surgical intervention.^[4] Since 3-dimensional image of the mass and its invasion to adjacent tissues can be obtained with CT, basic sinus X-rays may cause waste of time and unnecessary expenditures. CTs obtained for sinus tumors for the examination of changes in cranial and facial bones and assessment of the spread of the disease into soft tissue in combination with MR contribute greatly to surgical planning.^[5]

In this study, our aim was to present the presenting symptoms, clinical findings, locations of lesions, results of the histopathological examinations and treatment approaches in the light of the literature.

Materials and Methods

Study Design

A total of 73 patients who underwent incisional or excisional biopsies due to the unilateral intranasal mass lesions in the otorhinolaryngology clinic of our university between January 2012 and October 2014 were included in the study.

Outcome Parameters

Medical files of all patients enrolled in the study were retrospectively analyzed. Clinical histories, examination findings of the patients and histopathological diagnoses indicated in pathology archives were recorded. Patients with any missing data were excluded from the study. Histopathology results were classified as malignant and benign tumors and non-neoplastic lesions

Statistical Analyses

Data were analyzed using the IBM Statistical Package for Social Sciences v15 (SPSS Inc., Chicago, IL, USA). Parametric tests were applied to data of normal distribution and non-parametric tests were applied to data of questionably normal distribution. Data were expressed as mean±SD or median (interquartile range), as appropriate. Statistical significance was assumed for $p < 0.05$.

Results

A total of 73 patients who underwent incisional or excisional biopsy procedures because of unilateral intranasal mass lesions were included in the study. Of the 73 patients (41 males and 32 females) whose charts were reviewed, the median age was 41.74 (range: 1 to 74) years.

Intranasal masses were in the left ($n=35$; 47.9%) and right ($n=38$; 52.1%) nasal cavities. Nasal obstruction was the most frequent cause of referrals to the hospital. Among primary admission complaints, nosebleed was seen in 11 (69%) neoplastic and 22 (32%) in non-neoplastic cases. This intergroup difference observed was statistically significant ($p < 0.05$). Other presenting complaints consisted of nosebleed, headache, swelling around eyes, loss of vision and facial paralysis.

Neoplastic ($n=16$) and non-neoplastic ($n=57$) pathologies were detected in 73 patients participated in the study. Non-neoplastic lesions consisted of inflammatory polyps ($n=16$), chronic sinusitis ($n=11$), anthrocoanal polyps ($n=6$), retention cysts ($n=6$), rhinolith ($n=4$) (Fig. 1), concha bullosa ($n=4$), pyocele of concha bullosa ($n=1$), allergic fungal sinusitis ($n=1$), chronic fungal sinusitis ($n=2$) (Fig. 2), acute fulminant invasive fungal sinusitis ($n=1$), angiomatous polyp ($n=1$) and mucoceles ($n=4$) (Fig. 3) (Table 1). Neoplastic group ($n=16$) constituted of 2 malignant and 14 benign cases which were classified as inverted papillomas ($n=8$), adenocarcinoma ($n=1$) (Fig. 4), adenoid cystic carcinoma ($n=1$), hemangioendothelioma ($n=1$), capillary hemangioma ($n=1$), fibrous dysplasia ($n=1$) (Fig. 5), osteoma ($n=1$) (Fig. 6) and pyogenic granuloma ($n=2$) (Table 2).

Discussion

Unilateral sinonasal mass lesions comprise 6% of all paranasal pathologies.^[6] Inflammatory or neoplastic etiologies play a role in its etiology. In a study by Kahveci et al. on 127 cases, 25.2% of the cases with unilateral sinonasal masses were found to be related to neoplastic and 74.8% of them to inflammatory causes.^[7] Among these etiologies

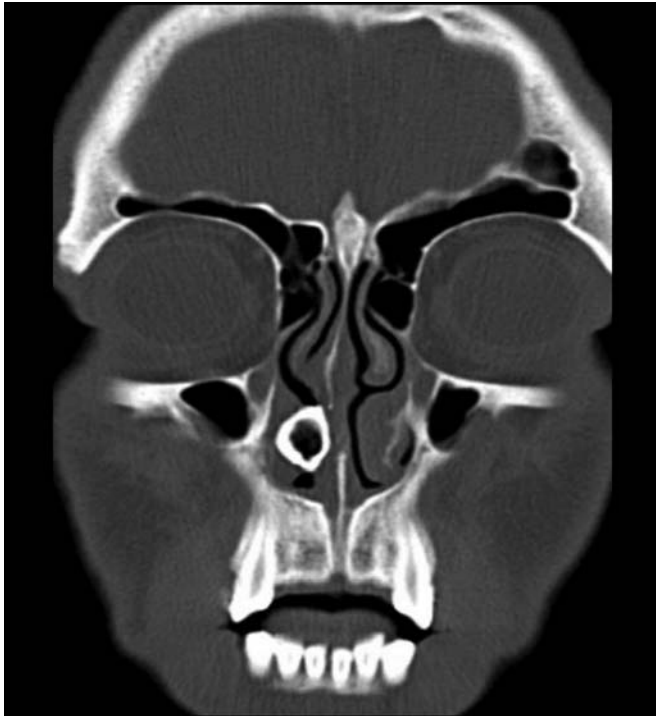

Fig. 1. Coronal CT showing rhinolith in the right nasal cavity.

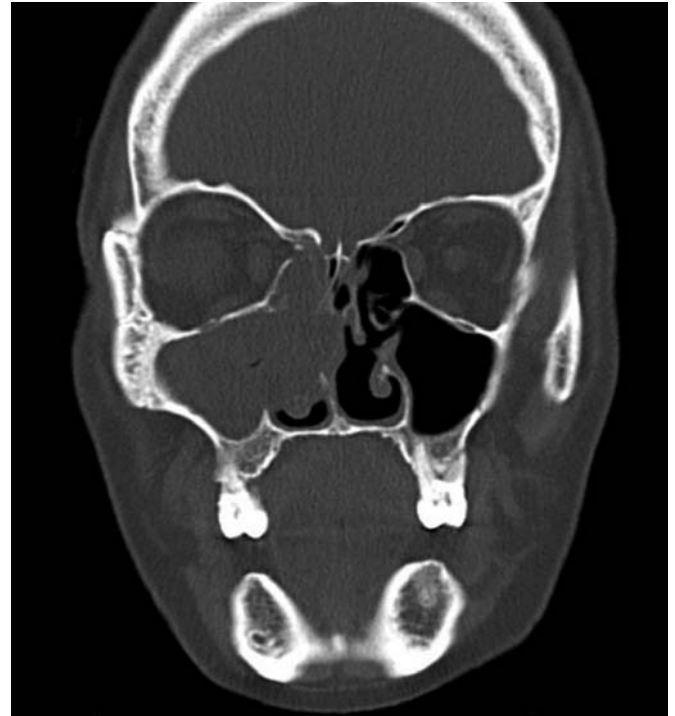


Fig. 2. Coronal CT showing chronic fungal sinusitis in the right nasal cavity.

nasal polyposis, mucocele, inverted papilloma, benign and malignant lesions of the minor salivary glands, hemangioma, neurogenic tumors, epidermoid carcinoma,

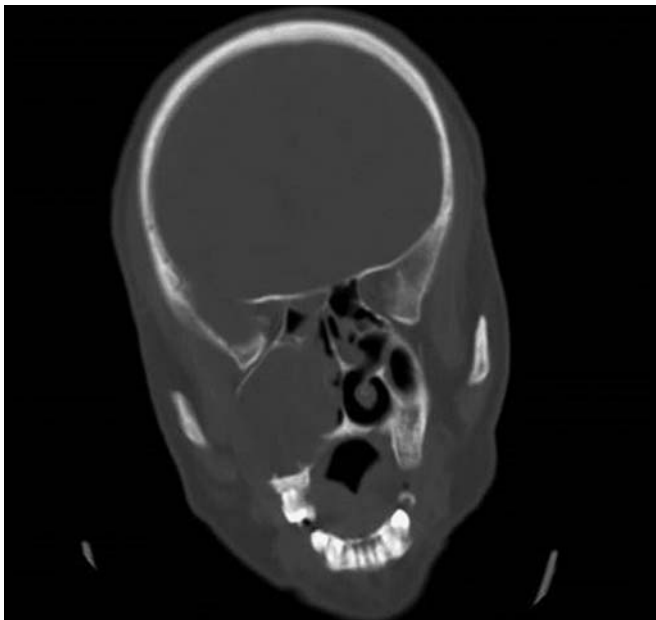


Fig. 3. Coronal CT showing giant mucocele in the right nasal cavity.

leukemia and lymphoma can be enumerated.^[3] However, in our study 16 neoplastic and 57 non-neoplastic lesions were detected in a total of 73 patients.

The most prominent symptoms in cases with paranasal sinus tumors are facial pain or tooth ache, nasal obstruction and/or nosebleed. As tumor gets larger in size, additional signs can emerge following invasion of the sur-

Table 1. Non-neoplastic pathologies observed in the study group.

	n
Inflammatory polyp	16
Chronic sinusitis	11
Anthrocoanal polyp	6
Retention cysts	6
Mucocele	4
Rhinolith	4
Concha bullosa	4
Pyocele of concha bullosa	1
Chronic fungal sinusitis	2
Allergic fungal sinusitis	1
Acute fulminant invasive fungal sinusitis	1
Angiomatous polyp	1

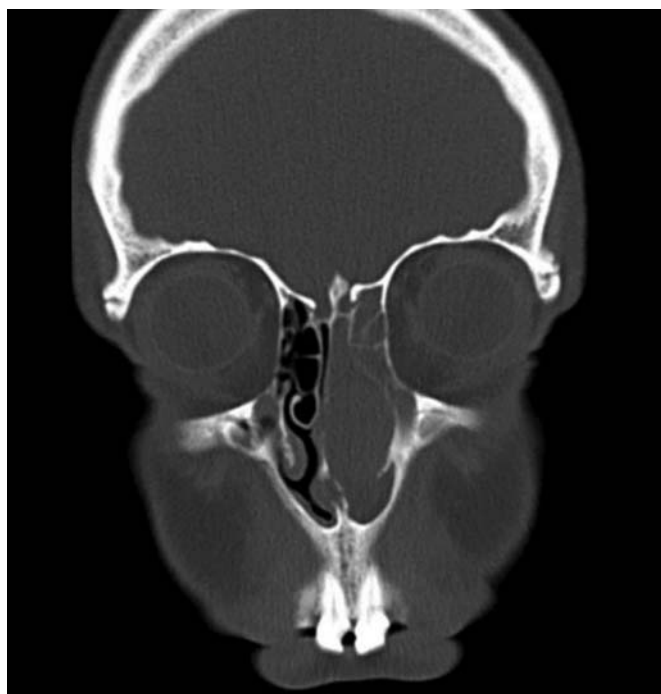

Fig. 4. Coronal CT showing adenocarcinoma in the left nasal cavity.

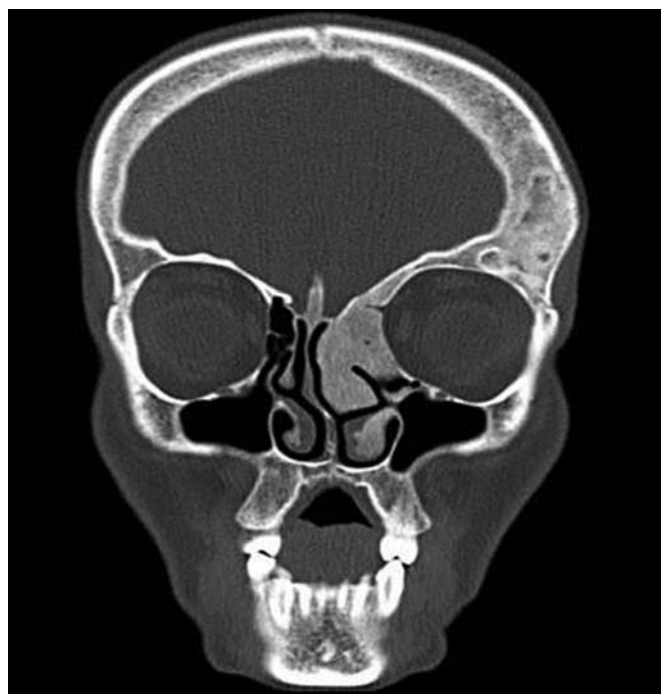


Fig. 5. Coronal CT showing fibrous dysplasia in the left nasal cavity.

rounding tissues. Diplopia or loss of vision, compression on orbita or invasion of optic nerve or oculomotor nerve, epiphora, occlusion of lacrimal duct localized on the anteromedial wall of maxilla, facial swelling or malocclu-

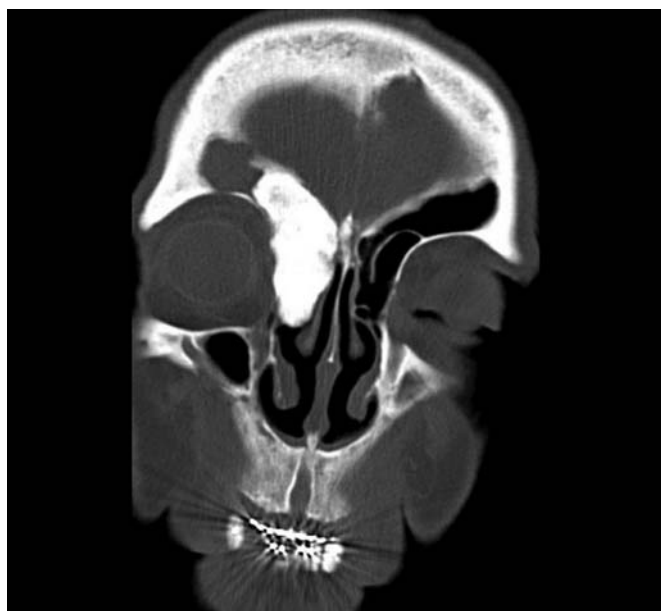


Fig. 6. Coronal CT showing osteoma in the right nasal cavity.

sion, progression of the sinonasal lesion into facial bones or nasal root, trismus; cervical mass following invasion of especially pterygoid muscles by advanced tumors; metastatic adenopathy caused by invasion of advanced tumors into jugular lymph drainage, loss of hearing occur. Generally tumors progress into nasopharynx leading to development of serous otitis, facial numbness. Besides, partial invasion or compression of trigeminal nerve occur.^[2,3] In our cases, nasal obstruction was observed as the most frequent admission complaint. Primary reason of admission was nasal obstruction in 46 (63%) patients. Other reasons of admission, in order of decreasing frequency, were nose-bleed, headache, swelling around eyes, loss of vision and facial paralysis.

Table 2. Neoplastic pathologies observed in the study group.

Malignant	n	Benign	n
Adenocarcinoma	1	Inverted papilloma	8
Adenoid cystic carcinoma	1	Pyogenic granuloma	2
		Capillary hemangioma	1
		Fibrous dysplasia	1
		Osteoma	1
		Hemangioendothelioma	1

When the presence of intranasal neoplasm was detected, paranasal sinus CT should be preferred as for detailed imaging.^[4] Since three dimensional image of the mass and its invasion into neighbouring tissue can be obtained by CT, basic sinus X-rays will be time-consuming and incur extra expenditures. CTs obtained for sinus tumors for the examination of the changes in cranial and facial bones and assessment of the spread of the disease into soft tissue by CT in combination with MR contribute greatly to surgical planning.^[5] We benefited from all of these imaging techniques in our cases excluding cases with hemangioma and hemangioendothelioma.

If malignancy is suspected after the first radiological imaging of intranasal masses, biopsy material obtained from the mass under local anesthesia will determine the treatment modality to be applied before the surgical intervention. However, in cases where benign and malignant pathologies coexist, inflammatory tissue surrounds tumoral tissue which may preclude acquirement of biopsy material from deeper tissues potentially leading to erroneous diagnosis.^[8] During biopsizing unilateral intranasal masses, probable presence of vascular tumor or encephalocele should be kept in mind. Before taking biopsy material, tumoral mass should be palpated with an instrument to discriminate between solid and cystic lesions. If the mass has a soft consistency or cystic structure, Valsalva manoeuvre is requested from the patient during endoscopic inspection of the mass. During this manoeuvre, enlargement of the mass demonstrates a potential intracranial or a venous communication of the mass. If suspicion is still maintained after this procedure, needle aspiration biopsy should be performed before excisional biopsy. If aspirate contains cerebrospinal fluid or diffuse hemorrhagic fluid, CT imaging or angiography should be planned before biopsy.^[3] Incisional and excisional biopsies were obtained under local anesthesia in order to establish the final diagnosis of all of our cases; however, any intra-, or postoperative surprising diagnosis was not encountered.

Inverted papilloma is a locally aggressive, but benign lesion. Generally they appear as a unilateral polypoid nasal mass.^[9] In order not to overlook these tumors which are occasionally associated with allergic nasal polyps, biopsy materials obtained from each passage should be sent separately to histopathological examination. Inverted papillomas can contain squamous, transitional or respiratory epithelium. Incidence of malignant transformation is accepted to be nearly 10 percent.^[3] Since even in the absence of malignant transformation, inadequate surgical excision is an etiological factor for recurrence, these tumors should be managed attentively. Classical surgical approach is lateral rhinotomy

or medial maxillectomy using a degloving procedure. However, in carefully selected cases, tumor can be totally excised using an endoscopic approach. Radiotherapy is ineffective and increases risk of malignant transformation.^[10] Eight out of 46 cases consisted of inverted papillomas. Endoscopic^[6] and external surgical approaches^[2] were used for our cases. The longest follow-up period was 1.5 years for one patient; however, any episode of recurrence was not encountered.

Hemangiomas generally originate from skin and oral mucosa. They are rarely seen in the nasal cavity.^[11] These lesions are usually asymptomatic. Excision of symptomatic lesions is recommended. For larger hemangiomas, preoperatively, angiography and selective embolization should be performed. Nasopharyngeal angiofibroma is a benign but locally destructive tumor. It is seen more frequently in adolescent male individuals. Angiofibromas, stem from a point on the posterolateral wall of the nasal ceiling where sphenoidal process of the palatine bone is fused with vomer and pterygoid process of the sphenoid bone. Tumor generally fills nasopharynx and extends into the nasal cavity. Tumor is a lobulated pink-red coloured mass. The most important bleeding comes from a. maxillaris interna. Endoscopic resection of the tumor has been the most preferred surgical treatment in recent years.^[12] Two of our cases admitted to our clinic with epistaxis developed secondary to a vascular lesion. Among these lesions, hemangioendothelioma is known as a very rare nasal mucosal pathology.

Osteomas gradually develop benign tumors from mature bone tissue. Osteomas are most frequently localized in mandibula.^[3] Among paranasal sinuses, most frequently they involve ethmoid and maxillary sinus. Sphenoid sinus is very rarely affected. Osteoplastic flap procedure is the best technique for the management of frontal sinus osteomas. For ethmoid sinuses, endoscopic or external ethmoidectomy and for maxillary sinus Caldwell-Luc procedure are the best approaches.^[3] In one patient with osteoma, the mass was localized in the frontal sinus. Osteoplastic flap surgery was preferred for one of our patient with headache and swelling around orbita. Fibrous dysplasia is one of the fibro-osseous lesions which are characterized with replacement of normal bone tissue by collagenous, various amounts of osteoid tissue and fibroblasts.^[2] It can be monostatic or polystatic. In monostatic types, maxillary bone is the one affected most frequently. It develops slowly and remains unchanged during the adult ages. Therefore, unless it causes functional and cosmetic problems, surgical intervention is not required. Radiotherapy has no place in its treatment; on the contrary, it increases the risk of malignant osteogenic sarcoma.^[2] We performed endonasal endoscopic biopsy and obtained tissue

specimen for definitive diagnosis of the patient who was referred to us from the department of medical oncology with the initial diagnosis of fibrous dysplasia. We did not perform surgical intervention for the patient who had not esthetic concerns and any functional problem.

Sinonasal malignancies constitute 1% of all and nearly 5% of head and neck malignancies.^[13,14] Seventy-five percent of the patients are aged 50 and over.^[15] More than 70% of malignant neoplasias of the nose and paranasal sinuses are squamous-cell cancers. In up to 70% of the cases, maxillary involvement is detected, followed by nasal cavity (20%) and other sinuses (10%). Multiple number of natural ostia and thin bony walls of paranasal sinuses facilitate tumoral spread from one compartment into another. Squamous cell carcinoma is mostly seen between 55 and 65 years of age with a male predominancy. In 15% the cases, bilateral tumors secondary to septal perforation and also in 15% of the patients synchronous and metachronous primary tumors are observed.^[2] They have keratinized and non-keratinized forms. They demonstrate more improved prognosis compared with tumors in other locations. In our cases squamous-cell cancer was not detected.

Adenoid cystic carcinoma is the most frequently seen malignant salivary gland tumor localized in the sinonasal region.^[2] Generally maxillary sinus (48%) involvement is observed which is followed by nasal cavity (24%), ethmoid sinus (16%) and sphenoid sinus involvements. It is most frequently seen in 30 to 50-year-old male patients. During its early phase, they can demonstrate perineural invasion. It has higher rates of local and distant metastases. Primary lesion of our case with adenoid cystic carcinoma was localized on the hard palate with its extensions into the base of the nasal cavity and of maxillary sinus. Inferomedial maxillectomy was performed using mid-fascial degloving method and any incident of recurrence was not detected during our 1.5-years of follow-up period. Adenocarcinomas are most frequently localized in antrum, ethmoid sinus and nasal cavity.^[2,3] Generally they appear as masses invading surrounding bony structures. They have mucinous, papillary, trabecular, clear-cell, apocrine, papillary and tubulocystic forms. They are radiosensitive tumors; however, surgery is the treatment modality preferred first. CT of the patient who presented with complaints of nosebleed and a mass lesion filling nasal cavity demonstrated involvement of all sinuses. Histopathology of the incisional biopsy material was reported as adenocarcinoma. Since the patient preferred to be operated in an external center, she was lost to our follow-up. Malignancy was detected in 2 (2.7%) of 73 cases we evaluated. In the literature, malignancy potential of unilateral nasal masses was reportedly at comparatively higher levels. We

obtained lower incidence rates because of our scarce number of patients with malignancies.

Hemangioendothelioma is a term used for a family of neoplastic lesion family which demonstrates a biological behaviour between angiosarcoma and benign hemangioma.^[16,17] Its malignant subtypes demonstrate small differences as for malignancy potential; however, they rarely metastasize. They more frequently involve soft tissues and rarely skin and mucosal surfaces and seen most frequently in lower extremities. Head and neck and especially sinonasal mucosa are involved less frequently.^[16,18] Nasal cavity hemangioendotheliomas manifest nonspecific symptoms such as nosebleed, nasal obstruction and crusting.^[17,19] In our series, our 70-year-old female case admitted to our outpatient clinic with the complaint of nosebleed. On physical examination, a lesion with a moderate solidity, large base, smooth surface measuring nearly 1 cm in diameter and 0.5 cm in height localized on the right side of the nasal septum on the Little area was seen. With initial diagnosis of lobular capillary hemangioma (pyogenic granuloma), the lesion was excised completely with surrounding intact mucosa and underlying cartilage and perichondrium. Histopathological examination was reported as hemangioendothelioma. However, pyogenic granuloma is usually a rapidly developing benign fibrovascular lesion generally originating from skin and oral mucosa. Although it is seen at every age, it is more frequently observed in the 3rd decade and female gender. Lobular capillary hemangioma is most frequently seen in buccal mucosa, gingiva, lips and tongue. It is rarely observed inside nasal cavity. In our 2 cases, excisional biopsy obtained following recurrent episodes of epistaxis established the diagnosis of pyogenic granuloma.

One of the etiological agents playing a role in sinusitis is fungi. Various incidence rates of fungal infections have been reported as 12% (Grigoriv et al.), 28.7% (LasKowinck et al.), and 10% (Stamberger et al.).^[20-22] The most frequent infections are *Aspergillus* and *Candida* infections (28). Cases with fungal sinusitis are divided into 4 groups as allergic, chronic invasive and noninvasive and acute fulminant sinusitis. Seventy percent of the case presentations with acute fulminant sinusitis were patients with diabetic ketoacidosis.^[23] Immunosuppressive patients, patients with multiple myeloma, AIDS, renal failure, cirrhosis and iron overload have been reported to be under risk. In addition to all of these predisposing diseases, though rarely, acute fulminant sinusitis can be seen in healthy individuals.^[23,24] From our series, we presented a 65-year-old patient with intractable diabetes who developed symptoms with progressive cranial nerve involvement. Her nasal endoscopy revealed presence of purulent secretion without black-

coloured crusts typical for fungal infections. Computed tomograms of paranasal sinuses disclosed signs of maxillary, ethmoid and frontal sinusitis. During monitorization of the patient, the disease progressed which necessitated recurrent biopsies from nasal cavity and paranasal sinuses. As a result of microbiological examinations *Rhizopus oryzae* was detected. Priorly normalization of blood glucose levels was attempted. After surgical intervention and antifungal treatment, progression of the disease was stopped and partial improvement in cranial symptoms was achieved.

Conclusion

Patients with unilateral nasal symptoms should be examined attentively. Unilateral nasal masses should be considered to be malignant lesions unless proved otherwise. The extension of the disease should be evaluated using preoperative imaging modalities. Incisional and excisional biopsy materials should be obtained from all patients. In cases of persistent clinical suspicion, recurrent biopsies should be performed from deeper tissues. Otherwise, the treatment of the misdiagnosed patients can be interrupted and their prognosis can be adversely affected.

Conflict of Interest: No conflicts declared.

References

- Ikeda K, Tanno N, Suzuki H, Oshima T, Kano S, Takasaka T. Unilateral sinonasal disease without bone destruction. Differential diagnosis using diagnostic imaging and endonasal endoscopic biopsy. *Arch Otolaryngol Head Neck Surg* 1997;123:198–200.
- Uysal İÖ, Misir M, Polat K, et al. Primary malignant melanoma of the nasal cavity. *J Craniofac Surg* 2012;23:e2–5.
- Bohman A, Oscarsson M, Holmberg K, Johansson L, Millqvist E, Nasic S, Torinsson-Nalwai A, Bende M. Heredity of nasal polyps. *Rhinology* 2015;53:25–8.
- Ahsan F, El-Hakim H, Ah-See KW. Unilateral opacification of paranasal sinus CT scans. *Otolaryngol Head Neck Surg* 2005;133:178–80.
- Lehnerdt G, Weber J, Dost P. Unilateral opacification of the paranasal sinuses in CT or MRI: an indication of an uncommon histological finding. *Laryngorhinootologie* 2001;80:141–5.
- Rudralingam M, Jones K, Woolford TJ. The unilateral opaque maxillary sinus on computed tomography. *Br J Oral Maxillofac Surg* 2002;40:504–7.
- Kahveci OK, Duran A, Miman MC. Our histopathological result for intranasal masses: Retrospective study of 6 years. *J Clin Anal Med* 2012;3:289–92.
- Han MW, Lee BJ, Jang YJ, Chung YS. Clinical value of office-based endoscopic incisional biopsy in diagnosis of nasal cavity masses. *J Otolaryngol Head Neck Surg* 2010;143:341–7.
- Ikiz AÖ, Sutay S, Edag TK, Guneri EA. İverted papillom ve cerrahi tedavisi. *KBB ve BBC Dergisi* 2001;134–8.
- Unlu HH, Songu M, Ovali GY, Nese N. Inverted papilloma with new bone formation: report of three cases. *Am J Rhinol* 2007;21:607–10.
- Chi TH, Yuan CH, Chien ST. Lobular capillary hemangioma of the nasal cavity: a retrospective study of 15 cases in taiwan. *Balkan Med J* 2014;31:69–71.
- Rogers DJ, Bevans SE, Harsha WJ. Endoscopic resection of juvenile nasopharyngeal angiofibroma. *Adv Otorhinolaryngol* 2012;73:132–6.
- Rinaldo A, Eerlito A, Shaha AR, Wei WI. Is elective neck treatment indicated in patients with squamous cell carcinoma of the maxillary sinus? *Acta Otolaryngol* 2002;122:443–7.
- Tiwari R, Hardillo JA, Mehta D, et al. Squamous cell carcinoma of maxillary sinus. *Head Neck* 2000;22:164–9.
- Wolf J, Schmezer P, Fengel D, Schroeder HG, Scheithauer H, Woeste P. The role of combination effects on the etiology of malignant nasal tumours in the wood-working industry. *Acta Otolaryngol Suppl* 1998;535:1–16.
- Deyrup AT, Tighiouart M, Montag AG, Weiss SW. Epithelioid hemangioendothelioma of soft tissue: a proposal for risk stratification based on 49 cases. *Am J Surg Pathol* 2008;32:924–7.
- Di Girolamo A, Giacomini PG, Coli A, Castri F, de Padova A, Bigotti G. Epithelioid haemangioendothelioma arising in the nasal cavity. *J Laryngol Otol* 2003;117:75–7.
- Requena L, Kutzner H. Hemangioendothelioma. *Semin Diagn Pathol* 2013 ;30:29–44.
- Semino L, Pagella F, Delù G, et al. Endoscopic treatment of ethmoidal hemangioendothelioma: case report and review of the literature. *Am J Otolaryngol* 2006;27:287–90.
- Blitzer A, Lawson W. Fungal infections of the nose and paranasal sinuses. *Otolaryngol Clin North Am* 1993;26:1007–35.
- Cody T, Neel Hb, Ferreiro Sa, Roberts Gd. Allergic fungal sinusitis: The Mayo Clinic experience. *Laryngoscope* 1994;104:1074–9.
- Stammberger H. Endoscopic surgery for mycotic and chronic recurring sinusitis. *Ann Otol Rhinol Laryngol* 1985;119:1–11.
- Ferguson BJ. Mucormycosis of the nose and paranasal sinuses. *Otolaryngol Clin North Am* 2000;33:349–65.
- Songu M, Unlu HH, Gunhan K, Ilker SS, Nese N. Orbital exenteration: A dilemma in mucormycosis presented with orbital apex syndrome. *Am J Rhinol* 2008;22:98–103.

This is an open access article distributed under the terms of the Creative Commons Attribution-NonCommercial-NoDerivs 3.0 Unported (CC BY-NC-ND3.0) Licence (<http://creativecommons.org/licenses/by-nc-nd/3.0/>) which permits unrestricted noncommercial use, distribution, and reproduction in any medium, provided the original work is properly cited.

Please cite this article as: Kucur C, Oğhan F, Özbay İ, Erdoğan O, Tok Ş, Şanal B, Korkmaz M, Yıldırım N. Unilateral nasal pathologies: clinical presentation and management. *ENT Updates* 2015;5(1):23–29.