

# Actinomyces in concha bullosa: a case report

## Konka bullozada aktinomikoz: Olgu sunumu

Fethullah Kenar<sup>1</sup>, Şahin Ulu<sup>2</sup>, Hüsniye Dilek<sup>3</sup>, Abdullah Ayçiçek<sup>2</sup>, Hüseyin Yıldız<sup>2</sup>

<sup>1</sup>Department of Otorhinolaryngology, Faculty of Medicine, Pamukkale University, Denizli, Turkey

<sup>2</sup>Department of Otorhinolaryngology, Faculty of Medicine, Afyon Kocatepe University, Afyonkarahisar, Turkey

<sup>3</sup>Department of Pathology, Faculty of Medicine, Afyon Kocatepe University, Afyonkarahisar, Turkey

### Abstract

Actinomyces, a gram-positive, anaerobic-to-microaerophilic species of bacteria, lives as commensal in human body. In this report, actinomyces in concha bullosa in a 51-year-old woman is presented and it is aimed to add a case to the very rarely reported atypical locations of actinomyces. Also, diagnostic and therapeutic approaches were discussed. Actinomyces should also be considered in the differential diagnosis of the patients with effluent at head and neck region and nasal cavity in daily practice of otorhinolaryngology.

**Keywords:** Actinomyces, concha bullosa, middle turbinate, penicillin.

### Özet

Gram pozitif, anaerob-mikroaerofilik yapıda bir bakteri olan actinomyces, insan vücudunda kommensal olarak yaşar. Bu yazıda 51 yaşındaki kadın hastada konka bullozada aktinomikoz sunulmuş ve aktinomikozun çok ender bildirilen atipik yerleşimlerine bir olgu eklenmesi amaçlanmıştır. Aynı zamanda tanıl ve tedavi edici yaklaşımlar tartışılmıştır. Otorinolarinolojinin günlük pratiğinde, baş boyun bölgesi ve burun boşluğundaki akıntılı hastaların ayırıcı tanısında aktinomikoz da akıld tutulmalıdır.

**Anahtar sözcükler:** Aktinomikoz, konka bulloza, orta konka, penicilin.

Actinomyces is a gram-positive bacterium, which lives as commensal in the human body, especially in the upper aerodigestive system and can lead to chronic soft tissue infection. It has an anaerobic or microaerophilic character and production of it in the culture is quite difficult. It is mainly observed in 3 clinical forms: cervicofacial, pulmonothoracic and abdominopelvic. In humans cervicofacial actinomyces, which accounts for about half of the cases, is often seen in the corner of the mandible as a fluctuating and a progressively growing mass.<sup>[1]</sup>

Atypically located forms of actinomyces have been reported in addition to the main clinical forms. To the best of our knowledge, actinomyces of the nasal cavity has been reported very rarely in the literature, but actinomyces of concha bullosa has not been reported yet in English medical literature. In this study, we aimed to present a case of actinomyces in concha bullosa and to discuss the differential diagnosis and treatment.

### Case Report

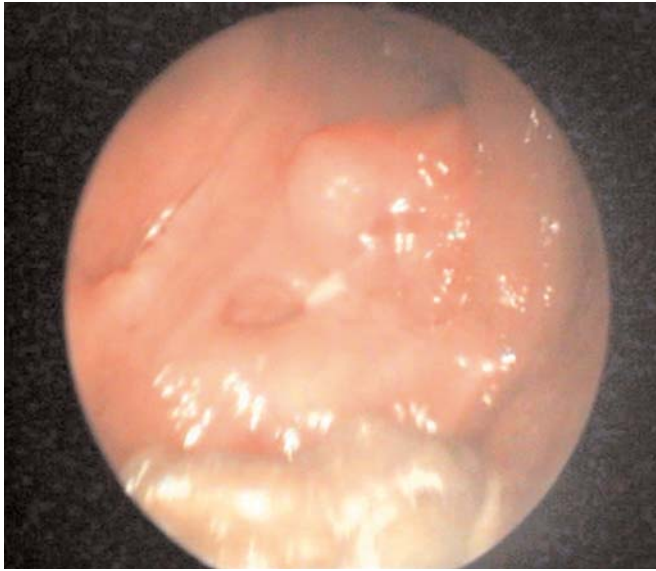
A 51-year-old female patient presented to our clinic with a complaint of nasal obstruction. The patient was suffering from nasal congestion for about 3 years. She had no systemic disease or history of nasal trauma. Allergic symptoms were prominent. There was no immunodeficiency in the medical history or at further laboratory investigations. Nasal examination revealed slightly right-sided septal deviation and a mass that almost filled the left nasal cavity which was lined with smooth mucous membrane. The lower portion of the mass had a polypoid appearance. At the diagnostic nasal endoscopy, a green-yellow-gray-colored material with granulation tissue between inferior and middle conchae and mucopurulent effluent in the left nasal cavity were observed (Fig. 1). Punch biopsy was performed and the cultures were taken after the aspiration of secretion. Paranasal sinus computed tomography (CT) scan showed a huge mass

**Correspondence:** Fethullah Kenar, MD. Department of Otorhinolaryngology, Faculty of Medicine, Pamukkale University, 20700, Denizli, Turkey.  
e-mail: fkenar@hotmail.com

**Received:** September 10, 2013; **Accepted:** November 12, 2013; **Published online:** May 5, 2014

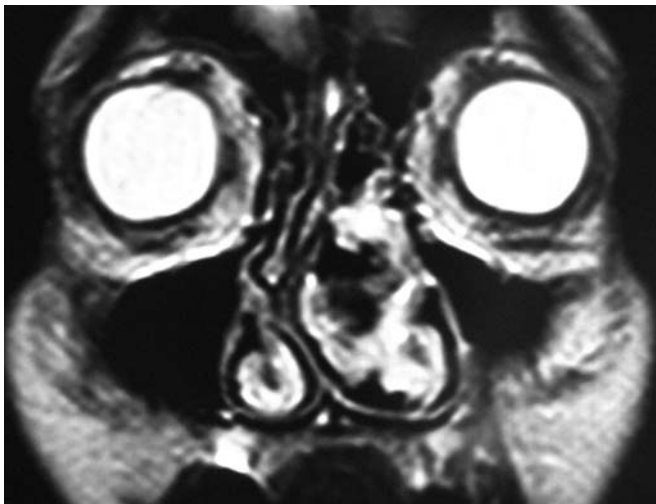
Online available at:  
www.jmedupdates.org  
doi:10.2399/jmu.2014001009  
QR code:



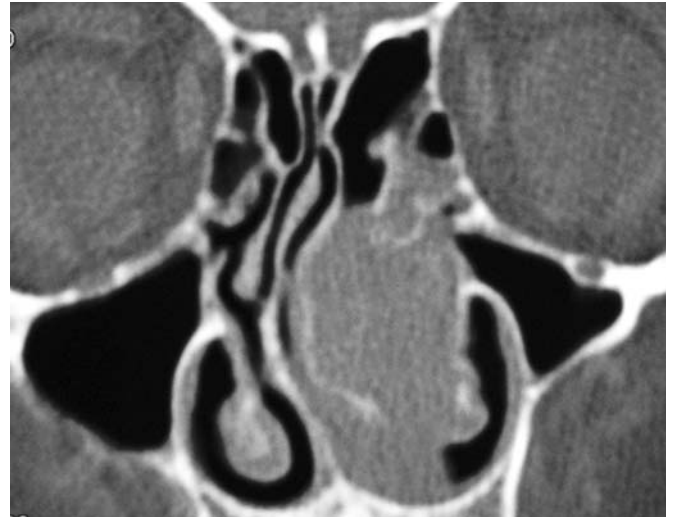

**Fig. 1.** Nasal endoscopic view of the left nasal cavity; a green-yellow-gray-colored material as a soft white cheese with granulation tissue and mucopurulent effluent is seen.

consistent with concha bullosa, which almost completely obliterates the left nasal cavity within the soft tissue density accompanying sparsely bone defects. Also displacement of the septum towards the right side by the mass was observed (Fig. 2). Paranasal sinus magnetic resonance (MR) imaging showed polypoid formation at the anterior part of the middle meatus of the left nasal cavity, which was enhanced after the injection of intravenous contrast agent, and demonstrated T2 hyperintensity and T1 hypointensity. The mass was

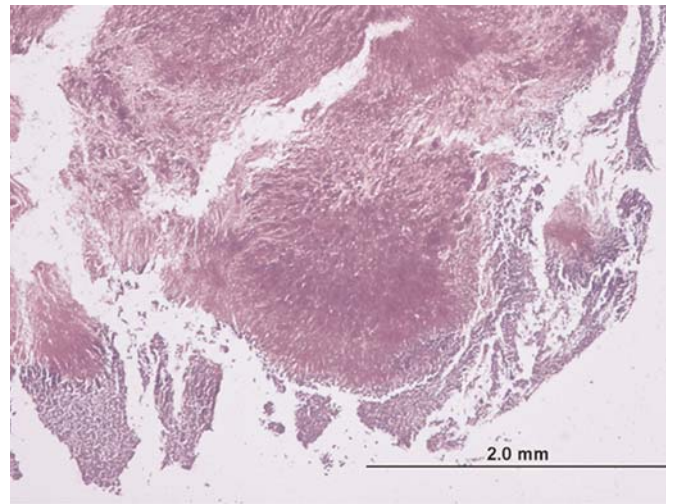


**Fig. 3.** Paranasal sinus MR image shows polypoid structure in the left nasal cavity.



**Fig. 2.** Coronal computed tomography without contrast agent image shows a huge mass consistent with concha bullosa, which almost completely obliterates the left nasal cavity within the soft tissue density accompanying sparsely bone defects and displacement of the septum towards the right side.

evaluated firstly as a nasal polyp. Hypertrophic middle turbinate, concha bullosa variation and right septal deviation were also reported in this localization (Fig. 3). Cultures of the lesion were negative. Pathological examination revealed inflammatory polyps, fibrin exudates and actinomyces (Fig. 4). Endoscopic sinus surgery was performed under general anesthesia. Bone and mucosal defects were observed at the large part of the lateral wall and local parts of the medial wall of the left middle turbinate. Middle



**Fig. 4.** Actinomycosis is characterized by sulphur granules that is branching as peripherally palisadic filaments (H&E x40).

turbinate was resected subtotally. At the post-operative period, the patient was treated with penicillin G and no incident occurred during post-operative period.

## Discussion

Actinomyces is a filamentous, gram-positive, non-acid-fast, anaerobic-to-microaerophilic species of bacteria. It cannot penetrate into the intact tissue. Mucosal damage is usually required to invade through subcutaneous tissues and to develop an infection. Common causes of actinomycosis are odontogenic reasons such as oromaxillofacial trauma, dental caries and dental manipulation. As actinomyces is not regarded as an opportunistic pathogen, poor oral hygiene and dental diseases are thought to be the main causes of the disease.<sup>[2]</sup>

Actinomycosis can be diagnosed by a positive culture. However, low rates of bacteria isolation in the culture make the diagnosis difficult. Accompaniment of lots of bacteria and abscess formation to actinomycosis also contribute to low rates of bacteria isolation in the culture. Negative culture was observed in our patient. Therefore, clinical and histopathologic examinations become important for the diagnosis.<sup>[1,3]</sup> Determination of sulphur granules in the histopathologic examination is characteristic, but can be seen approximately in only one third of the patients. In our case, the diagnosis was based on the detection of sulphur granules and related granuloma at the biopsy specimens taken from the lesion. The diagnosis is difficult clinically, because the disease can be presented by many different clinical forms and can mimic many granulomatous, fungal and tumoral diseases. Although radiological findings of CT and MRI are non-specific, they become important in terms of showing adjacent structures in the patients who will undergo surgery.<sup>[1,4]</sup> In such a case, clinical suspicion emerges as the most important issue, because correct diagnosis can be achieved with combination of all diagnostic approaches.

Belmont et al. reported that they had diagnosed three of four atypically localized cervicofacial actinomycosis cases by culture and one of them by pathologic examination and they provided adequate resolution by the penicillin treat-

ment for 4-6 weeks.<sup>[1]</sup> Özcan et al. reported actinomycosis after the pathologic examination of the surgical excision biopsy material obtained from an intranasal mass which did not respond to the treatment with amoxicillin-clavulanate for 20 days and they have emphasized the importance of actinomycosis in the differential diagnosis of nasal obstruction and nasal cavity mass.<sup>[5]</sup> In intranasal actinomycosis, endoscopic sinus surgery is recommended for the excision of the lesion and the debridement of surrounding tissue.<sup>[5]</sup> In our case, sufficient excision could be performed by endoscopic approach. In the treatment of actinomycosis, antibiotic therapy is recommended for 4-6 weeks with or without surgical debridement. Although penicillin is preferred in the first stage, erythromycin and tetracycline are recommended in patients resistant to penicillin.<sup>[6]</sup> Our patient was treated with penicillin G for 4 weeks after surgical excision and revealed no evidence of the disease at the control examination.

In conclusion, though it is rarely seen in the practice of otorhinolaryngology, actinomycosis should be considered in the differential diagnosis of the patients with effluent at head and neck region and nasal cavity that any definite micro-organism cannot be isolated in the culture and do not respond to long-term treatment with antibiotics.

**Conflict of Interest:** No conflicts declared.

## References

1. Belmont MJ, Behar PM, Wax MK. Atypical presentations of actinomycosis. *Head Neck* 1999;21:264-8.
2. Bennhoff DF. Actinomycosis: diagnostic and therapeutic considerations and a review of 32 cases. *Laryngoscope* 1984;94:1198-217.
3. Baliga S, Shenoy S, Wilson G, Katara V. An unusual case of actinomycosis. *Ear Nose Throat J* 2002;81:44-5.
4. Park JK, Lee HK, Ha HK, Choi HY, Choi CG. Cervicofacial actinomycosis: CT and MR imaging findings in seven patients. *Am J Neuroradiol* 2003;24:331-5.
5. Özcan C, Talas D, Görür K, Aydın Ö, Yıldız A. Actinomycosis of the middle turbinate: an unusual cause of nasal obstruction. *Eur Arch Otorhinolaryngol* 2005;262:412-5.
6. Kawai M, Mizutani H, Ueda M, Hoshino T, Kaneda T. Cervicofacial actinomycosis: report of two cases. *Nagoya J Med Sci* 1993;55:83-8.

This is an open access article distributed under the terms of the Creative Commons Attribution-NonCommercial-NoDerivs 3.0 Unported (CC BY-NC-ND3.0) Licence (<http://creativecommons.org/licenses/by-nc-nd/3.0/>) which permits unrestricted noncommercial use, distribution, and reproduction in any medium, provided the original work is properly cited.

Please cite this article as: Kenar F, Ulu Ş, Dilek H, Ayçiçek A, Yıldız H. Actinomycosis in concha bullosa: a case report. *J Med Updates* 2014;4(1):40-42.