

Extranasopharyngeal angiofibroma originating from sphenoid sinus: a case report

Sfenoid sinüs kökenli ekstranazofaringeal anjiyofibrom: Olgu sunumu

Turhan San¹, Muhammet Tekin¹, Osman Halit Çam¹, Adem Kılıçaslan¹, Ebru Zemheri²

¹Department of Otorhinolaryngology, İstanbul Medeniyet University, Göztepe Training and Research Hospital, İstanbul

²Department of Pathology, İstanbul Medeniyet University, Göztepe Training and Research Hospital, İstanbul

Abstract

Angiofibromas typically arise from the nasopharynx in young adolescent males. Extranasopharyngeal angiofibroma (ENA) implicates the vascular fibrous nodules occurring outside the nasopharynx. Since the clinical characteristics of ENA differ from those of nasopharyngeal angiofibroma, diagnosis can be challenging. Biopsy is usually discouraged due to the risk of bleeding. A high index of suspicion and a methodical evaluation are essential in establishing the proper diagnosis and treatment. We report the rare case of a 49-year-old woman who presented with headache and epistaxis. The mass was found to arise from right sphenoid sinus and total excision could be accomplished with endoscopic sinus surgery. Postoperative histopathologic analysis was consistent with an angiofibroma. To the best of our knowledge, only 3 cases of ENA arising from the sphenoid sinus have been previously reported in the English-language literature.

Key words: Sphenoid sinus, benign tumours, angiofibroma, extranasopharyngeal angiofibroma.

Özet

Anjiyofibromlar tipik olarak nazofarenksten köken alır ve adolesan erkeklerde görülür. Nazofarenks dışında görülen vasküler fibröz nodüller ekstranazofaringeal anjiyofibrom olarak adlandırılır. Ekstranazofaringeal anjiyofibromun klinik özellikleri, nazofaringeal anjiyofibromdan farklı olduğundan tanıda zorluklarla karşılaşılabilir. Biyopsi, kanama riski nedeniyle genellikle önerilmez. Doğru tanı ve uygun tedavi için klinik şüphe ve metodolojik yaklaşım önemlidir. Bu olgu sunumunda, baş ağrısı ve burun kanaması yakınmalarıyla başvuran 49 yaşında kadın hastada saptanan sağ sfenoid sinüs kökenli anjiyofibrom olgusu sunulmaktadır. Lezyon endoskopik sinüs cerrahisi ile total olarak rezeke edildi. Bildiğimiz kadarıyla literatürde daha önce sadece 3 sfenoid sinüs kökenli anjiyofibrom olgusu rapor edilmiştir.

Anahtar sözcükler: Sfenoid sinüs, benign tümör, anjiyofibrom, ekstranazofaringeal anjiyofibrom.

Angiofibroma is a vascular tumor observed more frequently in adolescent males and it is the most common benign tumor of nasopharynx.^[1] It originates from the sphenoid foramen at the junction of the root of the sphenoid process of palatine bone, horizontal ala of vomer and pterygoid process of sphenoid bone.^[2,3] When it occurs out of this site, it is termed as extranasopharyngeal angiofibroma (ENA). This rare tumor usually displays variable clinical presentation and was recently termed as “atypical angiofibroma” due to its distinct characteristic features.^[4-6] Thus, ENA can constitute a challenge in terms of diagnosis and treatment. To our knowledge, there have been only a few

ENA case reports in the literature. It is extremely rare in females.^[2] Although it sometimes involves the sphenoid sinus, it rarely originates from this site and only three such cases are reported in the literature.

In this paper, we present a rare case of ENA originating from sphenoid sinus in a 49-year-old woman presenting with headache and epistaxis.

Case Report

A 49-year-old woman suffering from headache and epistaxis for 1.5 months admitted to our clinic. There was no histo-

Correspondence: Turhan San, MD. İstanbul Medeniyet Üniversitesi, Göztepe Eğitim ve Araştırma Hastanesi, Kulak Burun Boğaz Hastalıkları Anabilim Dalı, İstanbul, Turkey.
e-mail: turhansan@gmail.com

Received: August 16, 2012; **Accepted:** October 11, 2012; **Published online:** January 12, 2013

Online available at:
www.jmedupdates.org
doi:10.2399/jmu.2012003007
QR code:



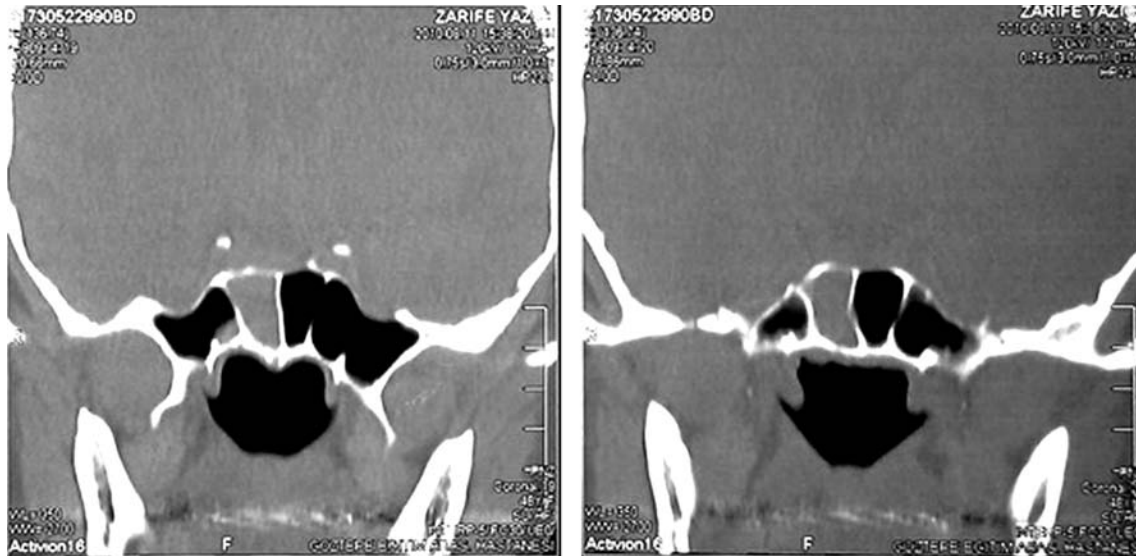


Fig. 1. Coronal tomographic view showing a soft tissue intensity in the right sphenoid sinus without bony erosion.

ry of recent trauma or infection, but she only had multinodular goiter with a history of surgery for cervical hernia 5 years ago. In endonasal examination, bilateral concha bullosa were observed without any evidence for discharge, crusting or bleeding in the nasal cavity. Neurologic examination was normal. Computerized tomography (CT) of paranasal sinuses showed a soft tissue in the right sphenoid

sinus without bony erosion (Fig. 1), whereas a cystic lesion was observed in the right sphenoid sinus under magnetic resonance imaging (MRI) (Fig. 2).

Endoscopic sinus surgery was performed under general anesthesia. Intraoperatively, the ostium of the sphenoid sinus was enlarged initially. Subsequent to the entry into the sphenoid sinus, the smooth-surfaced tumor with a size

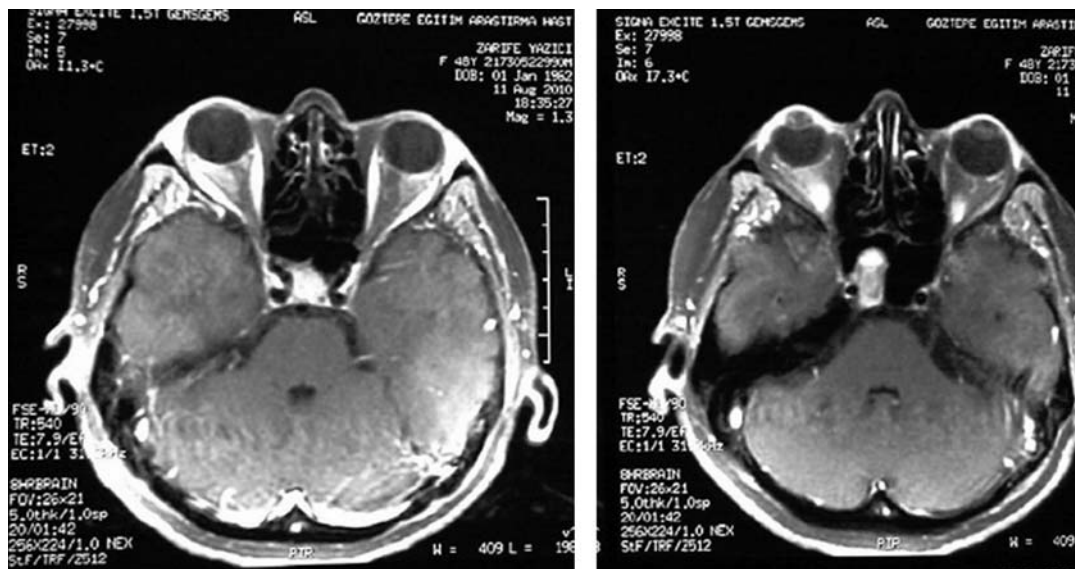


Fig. 2. Magnetic resonance imaging view demonstrating a cystic contrast-enhanced lesion in the right sphenoid sinus (T2 axial section).

of 1.5x1.5 cm was excised totally. The right sphenoid sinus and right nasal cavity was packed for 48 hours and the postoperative course was uneventful. The histopathological examination revealed fibroblastic proliferation in stroma, increased number of branching vascular structures, hemosiderin laden macrophages consistent with angiofibroma (Fig. 3). At 10 months' follow-up, the patient was free of recurrence.

Discussion

Angiofibroma is the most common tumor of nasopharynx that makes up 0.5% of total head and neck tumors. It typically occurs in the nasopharynx of young males in 1st and 2nd decades.^[1,4] Isolated ENA is rare. A review of 65 ENA cases yielded that the average age of ENA patients was 22.9 and only 26% of patients were female.^[3] Therefore ENA is different than nasopharyngeal angiofibroma in terms of age and gender predilection. Our case was original since sphenoid sinus is a quite uncommon location for ENA which most commonly arises in the maxillary sinus followed by the ethmoid sinus.^[2] Nasal septum, larynx, external ear, cheek, conjunctiva, oropharynx, retromolar trigone, middle and inferior turbinates are other reported sites of occurrence. As far as we know, only three cases originating from sphenoid sinus have been reported in the literature up to now. The presenting symptoms were visual disturbance, nasal obstruction, snoring, fever and cheek pain.^[7,8] In a patient with ENA of sphenoid sinus, isolated sphenoid sinusitis occurred due to the obstruction of the sphenoid sinus ostium and complaints were relieved with antibiotherapy. The chief complaints of our patient were epistaxis and headache.

Radiological examination is essential for establishing the correct diagnosis, making an appropriate treatment plan, determining the extent of the lesion and finding the supplying vessel.^[1,3,4] Measures such as CT, MRI and angiography can be used.^[1,2] Selective angiography clearly reveals the vascular pattern and hemodynamics of the tumor; however absence of hypervascularity in angiography does not fully exclude ENA.^[3] Computerized tomography and MRI can determine the extent of tumor including the skull base involvement, intracranial spread and its relationship with important vascular and neurological structures.^[9] Although bony erosion can be determined with CT, MRI is usually sufficient to show the cortical erosion and trabecular bone formation stimulated by tumor. Imaging of nasopharyngeal angiofibroma with a contrast agent leads to diffuse and usually homogenous

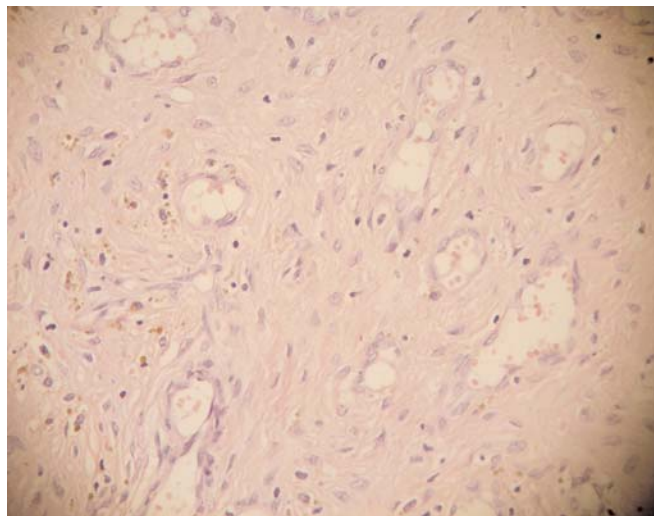


Fig. 3. Stromal fibroblastic proliferation and increased vascularization in angiofibroma (H-E x40).

involvement in CT and MRI T1 scans. In contrast, ENA enhances moderate amount of contrast or none due to its weak vascular involvement.^[10] Embolization can be utilized in cases with increased vascularity. Arteriography before biopsy or removal of tumor may reduce the risk of active bleeding. Since there was no evidence of bony destruction, involvement of soft tissue or increased vascularity in our case, only CT and MRI examinations were performed. Owing to the small size and limited extent of the lesion, minimal bleeding was expected during surgery and endoscopic sinus surgery was preferred.

The treatment of choice for angiofibroma is total surgical excision. Other treatment modalities include radiotherapy, cryosurgery, embolization, hormone therapy, chemotherapy, arterial ligation, sclerotherapy and watchful observation with the hope of spontaneous regression. Radiotherapy is less effective for ENA compared to nasopharyngeal angiofibroma.^[3]

Our case differs from a typical angiofibroma not only due to the age and gender of the patient, but also its site of origin and amount of bleeding. Total excision could be achieved with endoscopic sinus surgery. Angiofibroma must be included in the differential diagnosis of vascular tumors of nasal cavity and paranasal sinuses. Whether these lesions represent a true angiofibroma or variant of another lesion, is still under debate.

Conflict of Interest: No conflicts declared.

References

1. Akbas Y, Anadolu Y. Extranasopharyngeal angiofibroma of the head and neck in women. *Am J Otolaryngol* 2003;24:413-4.
2. Huang RY, Damrose EJ, Blackwell KE, Cohen AN, Calcaterra TC. Extranasopharyngeal angiofibroma. *Int J Ped Otorhinolaryngol* 2000;30:59-64.
3. Windfuhr JP, Remmert S. Extranasopharyngeal angiofibroma: etiology, incidence and management. *Acta Otolaryngol* 2004;124:880-9.
4. Nomura K, Shimomura A, Awataguchi T, Murakami K, Kobayashi T. A case of angiofibroma originating from the inferior nasal turbinate. *Auris Nasus Larynx* 2005;33:191-3.
5. Handa KK, Kumar A, Singh MK, Chhabra AH. Extranasopharyngeal angiofibroma arising from the nasal septum. *Int J Pediatr Otorhinolaryngol* 2001;58:163-6.
6. Somdas MA, Ketenci I, Unlu Y, Canoz O, Guney E. Extranasopharyngeal angiofibroma originating from the nasal septum. *Otolaryngol Head Neck Surg* 2005;133:647.
7. Reddy JB, Farb S. Angiofibroma of the sphenoid sinus. *Laryngoscope* 1963;73:108-19.
8. Lerra S, Nazir T, Khan N, Qadri MS, Dar NH. A case of extranasopharyngeal angiofibroma of the ethmoid sinus: a distinct clinical entity at an unusual site. *Ear Nose Throat J* 2012;91:E15-7.
9. Schick B, Kahle G. Radiological findings in angiofibroma. *Acta Radiol* 2000;41:585-93.
10. Harrison DF. The natural history, pathogenesis, and treatment of juvenile angiofibroma. Personal experience with 44 patients. *Arch Otolaryngol Head Neck Surg* 1987;113:936-42.

This is an open access article distributed under the terms of the Creative Commons Attribution-NonCommercial-NoDerivs 3.0 Unported (CC BY-NC-ND3.0) Licence (<http://creativecommons.org/licenses/by-nc-nd/3.0/>) which permits unrestricted noncommercial use, distribution, and reproduction in any medium, provided the original work is properly cited.

Please cite this article as: San T, Tekin M, Cam OH, Kilicaslan A, Zemheri E. Extranasopharyngeal angiofibroma originating from sphenoid sinus: a case report. *J Med Updates* 2012;2(3):120-123.