

Giant frontal pyomucocele*

Dev frontal piyomukosel

Salim Yüce¹, Mansur Doğan¹, İsmail Önder Uysal¹, Ayhan Dursun², İsmail Salk³, Emine Elif Altuntaş¹

¹Department of Otolaryngology, Faculty of Medicine, Cumhuriyet University, Sivas, Turkey

²Department of Ophthalmology, Faculty of Medicine, Cumhuriyet University, Sivas, Turkey

³Department of Radiology, Faculty of Medicine, Cumhuriyet University, Sivas, Turkey

Abstract

Giant mucoceles of the frontal sinus are rare but their recognition is important in the differential diagnosis of proptosis and fronto-orbital lesions. We describe a patient with frontal giant mucocele with intracranial as well as orbit and ethmoid sinus involvement. A 53-year-old male was admitted with headache, right exophthalmos and ophthalmoplegia. Computed tomography and magnetic resonance imaging demonstrated a giant frontal sinus mucocele with extension into the left anterior cranial fossa and orbit. The mucocele was treated with a transcranial and endoscopic transnasal approach.

Key words: Giant, frontal sinus, mucocele, external approach, endoscopic frontal sinusotomy.

Özet

Frontal sinüsün dev mukoseli ender görülmekle birlikte propitozis ve frontal-orbital lezyonların ayırıcı tanısında önemlidir. İntrakraniyal, orbital ve etmoid sinüse taşan frontal dev mukoseli olan bir olgu sunulmaktadır. Elli üç yaşındaki erkek hasta başağrısı, sağ ekzoftalmi ve oftalmopleji ile başvurmuştur. Bilgisayarlı tomografi ve manyetik rezonans görüntülemeye sol ön kraniyal fossaya ve orbitaya taşan dev frontal sinüs mukoseli saptanmıştır. Mukosel transkraniyal ve endoskopik transnazal yaklaşımla tedavi edilmiştir.

Anahtar sözcükler: Dev, frontal sinüs, mukosel, eksternal yaklaşım, endoskopik frontal sinüzotomi.

A paranasal mucocele is usually defined as an accumulation of mucosal secretions into a paranasal sinus with obstruction caused by inflammation, fibrosis, trauma, previous surgery, anatomical abnormality, or a mass lesion such as an osteoma.^[1] When the mucocele becomes infected, it is called a pyomucocele or pyocele, which contains pus partially or fully in cysts.^[2] The clinical manifestation of mucoceles is benign in most cases.^[1,2] Most mucoceles arise in the frontal and ethmoid sinuses, but intracranial extension is uncommon.^[1,3]

In this case report, we describe a case of a giant pyomucocele with extension into the anterior cranial fossa and orbit.

Case Report

A 53-year-old man presenting with right exophthalmos and ophthalmoplegia associated with swelling over the

right orbit and frontal region. He had complaints since the last one year. The patient's eyelid fell. No treatment applied to the patient. He went to an eye specialist because of the mass below the right eyelid 15 days ago. In the paranasal sinus computerized tomography (CT), a mucocele; approximately with the diameter of 3x1.5x3.5 cm, that fills in the whole frontal sinus and reaches to orbita by eroding the inferior sinus wall and compresses the orbita superiorly, was determined. Bone window CT also demonstrated a defect of the posterior wall of the frontal sinus, where the mucocele wall attached to the dura mater, and thinning and inferior depression of the superior orbital roof. Her right orbit was displaced toward the posterior ethmoid sinus. The patient's CT has a mass that extended from the anterior frontal cranium and right orbit

Correspondence: Salim Yüce, MD. Cumhuriyet Üniversitesi Tıp Fakültesi, Kulak Burun Boğaz Hastalıkları Anabilim Dalı, 58140, Sivas, Turkey.

E-mail: salimyucekbb@hotmail.com

Received: May 8, 2012; **Accepted:** July 23, 2012;

Published online: November 1, 2012

Online available at:
www.jmedupdates.org
doi:10.2399/jmu.2012002008
QR code:



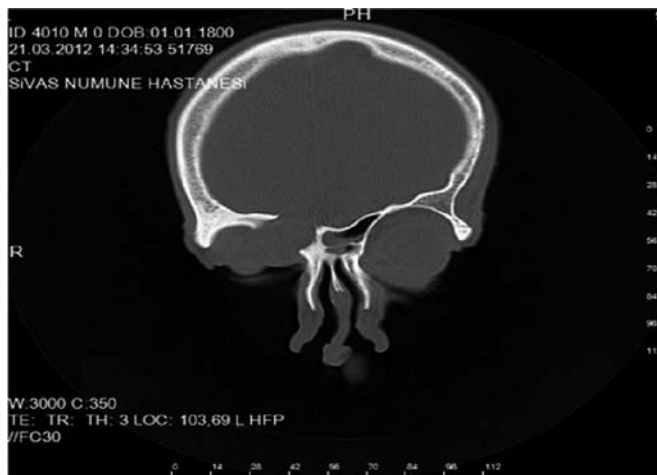


Fig. 1. Coronal CT scan demonstrated the giant frontal mucocele with extension into the right orbit and anterior ethmoid sinus.

were referred to the Department of Otolaryngology at the same hospital (Fig. 1). Magnetic resonance imaging (MRI) on admission revealed a large mass in the right frontal intracranial region. The mass lesion compressed the right frontal lobe (Fig. 2). The patient did not have any trauma story.

We planned for surgical excision of a giant frontal mucocele. A combined one stage external frontal sinusotomy and endoscopic transnasal approach were performed. After complete removal of the sinus mucosa, frontal sinus drainage (enlargement of the fronto-nasal duct) was achieved by a combined external trans-basal approach and endonasal endoscopic approach. The duramater over the frontal base was intact. Culture of the purulent fluid collection was negative. The postoperative course was uneventful, and all preoperative signs and symptoms resolved immediately after surgery.

Discussion

Even though frontal sinus mucocèles are benign and treatable lesions, they may cause serious complications through spreading to intracranial and intraorbital space with destruction of frontal sinus wall. Frontal sinus mucocèles represent a relatively rare, slow-growing pathology. They are usually clinically silent and are caused by the loss of drainage properties of the sinus mucosa. They can have orbital, anterior cranial fossa, and intracranial involvement. Posttraumatic or postoperative mucocèles can appear several years after the original event. Mucocèles

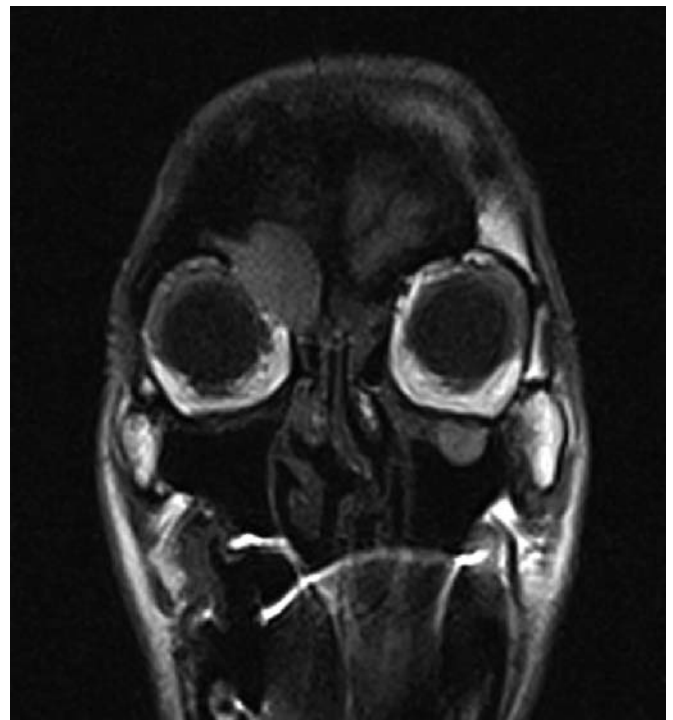

Fig. 2. Coronal MRI scan demonstrated the giant frontal mucocele with extension into the right orbit and anterior ethmoid sinus.

that result from trauma are mostly due to compromised ventilation, and can occur between 1 and 35 years later in the literature.^[4] Mucocèles are benign lesions that arise in the facial sinuses and result from accumulation of mucinous secretions due to obstruction of the ostium secondary to inflammation, trauma, anatomical aberrations, tumours and, rarely fibrous dysplasia. Frontal mucocèles have a silent clinical course so the patients usually present with headache and visual disturbance with the orbital and cranial extension at the end stages. In this case report, we presented 53-year-old male patient with headache, pain in the right eye and his eyelid fell for 1 year. But he did not have any trauma story. Surgical treatment strategies for mucocèles and fibrous dysplasia vary depending on sinus and intracranial involvement.

Conclusion

In conclusion, we advocate the use of pre-operative CT and MRI imaging and we believe combined technique (external frontal sinusotomy and endoscopic transnasal approach) to be very effective in giant frontal mucocele.

Conflict of Interest: No conflicts declared.

References

1. Nakayama T, Mori K, Maeda M. Giant pyocele in the anterior intracranial fossa - case report. *Neurol Med Chir (Tokyo)* 1998; 38:499-502.
2. Stankiewicz JA, Newell DJ, Park AH. Complications of inflammatory diseases of the sinuses. *Otolaryngol Clin North Am* 1993; 26:639-55.
3. Kawaguchi S, Sakaki T, Okuno S, Ida Y, Nishi N. Giant frontal mucocele extending into the anterior cranial fossa. *J Clin Neurosci* 2002;9:86-9.
4. Koudstaal MJ, van der Wal KG, Bijvoet HW, Vincent AJ, Poublon RM. Post-trauma mucocele formation in the frontal sinus; a rationale of follow-up. *Int J Oral Maxillofac Surg* 2004; 33:751-4.

This is an open access article distributed under the terms of the Creative Commons Attribution-NonCommercial-NoDerivs 3.0 Unported (CC BY-NC-ND3.0) Licence (<http://creativecommons.org/licenses/by-nc-nd/3.0/>) which permits unrestricted noncommercial use, distribution, and reproduction in any medium, provided the original work is properly cited.

Please cite this article as: Yüce S, Dogan M, Uysal IO, Dursun A, Salk I, Altuntas EE. Giant frontal pyomucocele. *J Med Updates* 2012;2(2):85-87.