

## Evaluation the effect of the Cartilaginous Columellar Strut Graft on Nasal Breathing Satisfaction after Septoplasty

### ABSTRACT

**Background:** Septoplasty is one of the most common operations in adults in order to improve qualitative and quantitative scores in nasal obstruction. Using Columellar strut graft in septoplasty is not a routine technique but helps not only to correct septal deviation but also provides a better breathing status. The aim of this study was to compare the outcome of routine septoplasty with septoplasty with Columellar strut graft in nasal breathing satisfaction.

**Methods:** Forty patients with deviated nasal septum who scheduled for septoplasty, were randomly assigned into 2 equal groups. In first group routine septoplasty and in second group septoplasty with columellar strut graft were performed. Visual Analog Scale (VAS) was used to evaluate nasal breathing satisfaction, and Nasal Obstruction Symptom Evaluation (NOSE) score was used for the assessment of nasal obstruction.

**Results:** According to VAS and NOSE score, nasal breathing satisfaction and nasal obstruction improved significantly in septoplasty with columellar strut graft group in comparison with the routine septoplasty group ( $P < .001$ ).

**Conclusion:** Using cartilaginous columellar strut graft in septoplasty is effective in improving nasal breathing satisfaction in patients after septoplasty. Therefore it should be recommended in septoplasties.

**Keywords:** Septoplasty, columellar strut, breathing, cartilaginous graft



### INTRODUCTION

Septoplasty is the most frequently performed operation in adults by ear, nose, throat (ENT) surgeons.<sup>1</sup>

Septoplasty is commonly performed to provide qualitative and quantitative benefit from straightening the septum.<sup>2</sup>

Nasal septum deviation is present in up to 80% of the general population, however, many cases are asymptomatic, and the degree of deviation has little or no correlation with the severity of obstruction.<sup>3</sup> Nasal obstruction affects about 9.5%-15% of community.<sup>4</sup>

Nasal obstruction results from many anatomic or structural causes such as nasal septum deviation and inferior turbinate hypertrophy and nasal and midfacial trauma and delivery trauma.<sup>5,6</sup> Nasal septum deviation may cause nasal congestion and discharge, sneezing, snoring, oral breathing, sleep apnea, and increased nasal airway sleep problems.<sup>7,8</sup>

Satisfaction from nasal breathing is directly related to quality of life and nasal obstruction has negative effects on patient's quality of life.<sup>9,10</sup>

Computed tomography (CT) scan is a useful tool for assessment the causes of nasal obstruction.<sup>11</sup>

Standard septoplasty was always carried out with minimal resection of the quadrangular cartilage and conservative repositioning of the vomer bone.<sup>12</sup> Appropriate surgical procedure will improve the patient's quality of life.<sup>13</sup>

Babak Mohajeri   
Mohammadebrahim  
Yarmohammadi   
Poopak Izadi 

Department of Otolaryngology,  
Shahed University Faculty of  
Medicine, Tehran, Iran

**Cite this article as:** Mohajeri B, Yarmohammadi M, Izadi P. The effect of the cartilaginous columellar strut graft on nasal breathing satisfaction after septoplasty. *ENT Updates*. 2024;14(1):1-4.

**Corresponding author:**  
Poopak Izadi

**E-mail:** popakizadi@yahoo.com

**Received:** September 2, 2023

**Revision Requested:** November 6, 2023

**Last Revision Received:** January 15, 2024

**Accepted:** January 29, 2024

**Publication Date:** March 21, 2024



Inappropriate surgical procedure leads to patients' dissatisfaction and recurrence of his problems.<sup>13</sup>

In order to achieve good nasal tip support and projection in rhinoplasty surgeries, usually the extracted part of lower quadrangular cartilage insert between medial cruras as columellar strut, but this is not routine in septoplasty.<sup>14</sup>

The purpose of this study was to evaluate nasal breathing satisfaction after septoplasty with preservation of extracted septal cartilage between medial cruras.

## MATERIAL AND METHODS

This prospective cohort randomized study performed in Shahid Mostafa Khomeini hospital during 2019 and 2020. Forty patients scheduled for septoplasty enrolled after explaining and signing a written informed consent. The Ethics committee of Shahed University approved this study as a medical student research proposal by number: IR.SHAHED.REC.1398.091 date: 2018.11.23. Patients randomly divided in 2 groups: 20 in routine septoplasty group and 20 in septoplasty with columellar strut graft. After scheduling the patients for surgery, Visual Analog Scale (VAS) and Nasal Obstruction Symptom Evaluation (NOSE) were recorded.

Inclusion criteria were adults between 18 and 60 years old with chronic nasal obstruction due to deviated nasal septum, lasting at least 3 months with no response to drug therapy.

Exclusion criteria were pregnancy, cancer, respiratory problems due to other causes such as: hypertrophy of nasal turbinates, allergic rhinitis, sinonasal infections and inflammatory diseases, septal perforation, craniofacial syndrome, nasal trauma or fracture. prior asthma, pulmonary disorders, any medical disorders (e.g., hypothyroidism) and drug use.

### Visual Analog Scale

The nasal breathing satisfaction in patients were recorded by visual analog scale (VAS) before and 6 months after septoplasty. Patients recorded the point on the scale from 0 to 10 according to their severity of nasal obstruction. Scoring in VAS is from 0 (no problem and complete nasal breathing satisfaction) to 10 (severe problem and least nasal breathing satisfaction)<sup>15</sup> (Figure 1).

### Nasal Obstruction Symptom Evaluation

Subjective perception of nasal patency evaluated by Nasal Obstruction Symptom Evaluation (NOSE) score. This is a valid,

reliable, brief, easy to complete for the patient and specific for nasal obstruction. NOSE questionnaire measures severity of nasal stuffiness, obstruction of nasal passage, nasal problem in breathing, sleep problem and difficulty in nasal breathing during exercise. It ranges from 0 (no subjective nasal obstruction) to 100 (severe subjective nasal obstruction).<sup>16</sup> Nasal Obstruction Symptom Evaluation scale score has confirmed by Lipan and Most as an effective tool for subjective assessment of postoperative nasal obstruction.<sup>17,18</sup>

### Technique of Surgery

Septoplasty carried out in all patients under general anesthesia by the same anesthesiologist and nose surgeon. then infiltration and hydrodissection of septum was performed with 2% lidocaine and epinephrine 1/100000. Routine technique using hemitransfixion incision at the caudal end of septum without trauma to membranous columella was done. After intact elevation of mucoperichondrial and mucoperiosteal flap from underlying septal cartilage and bone, the deviated parts of septum were removed. In order to stabilization of nasal dorsum and tip, an "L-strut" shape of quadrangular cartilage at inferior and dorsal parts has preserved for about 10-15 mm in width. Extracted parts of cartilage should be saved in normal saline or reshaped and used to reinforce the L-strut or can be used as grafts in rhinoplasty. We used from cartilages removed from septum as a cartilaginous strut graft (0.5 cm in width and the same height of the patient's nasal tip in height) between right and left medial crura through a vertical incision (3-5 mm) in distal part of nasal mucosa in second group. Then incisions were sutured and elevated flaps reattached to septum by 3-0 catgut quilting sutures to close dead spaces and preventing from septal hematoma. nasal packing was inserted at the end of the operation and removed 2 days after surgery.

### Statistical Analysis

At first the normality of informative data were tested with Kolmogorov-Smirnov test. The difference between pre and postoperative tests in 2 groups was evaluated by "oneway ANOVA" test. Statistical analyses were done using SPSS 20 (IBM SPSS Corp.; Armonk, NY, USA). *P*-value less than .05 was considered statistically significant. Pre- and postoperative subjective symptoms were evaluated by "Repeated Measures ANOVA" test.

## RESULTS

A total of 40 patients scheduled for septoplasty were enrolled in this study. There were 17 male (42.5%) and 23 female (57.5%).

## MAIN POINTS

- Septal cartilage is usually the best material for nose surgeries but it may be insufficient or missing during previous surgeries therefore in this manuscript we preserve the extracted cartilage pieces in columella.
- Using cartilaginous columellar strut graft in septoplasty is effective in improving nasal breathing satisfaction in patients after septoplasty.
- Satisfaction from nasal breathing is directly related to quality of life and nasal obstruction has negative effects on patient's quality of life.

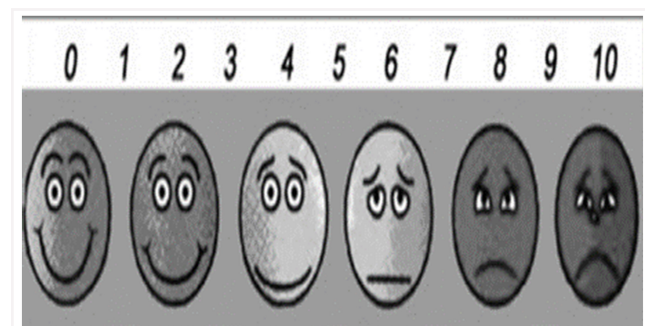


Figure 1. Visual Analog Scale (VAS).

**Table 1. Nasal Obstruction Symptom Evaluation Questionnaire**

Symptom	No Complaints	Mild	Moderate	Bad	Severe
Nasal congestion	0	1	2	3	4
Nasal obstruction	0	1	2	3	4
Problems in nasal breathing	0	1	2	3	4
Sleeping problems	0	1	2	3	4
Difficulties in nasal breathing during exercise or physical effort	0	1	2	3	4
Total score: 0-100.					

Scheduled patients were randomized into 2 groups: 20 underwent routine septoplasty (group 1) and 20 septoplasty with blunt cartilaginous columellar strut graft (group 2). Demographic characteristics were similar between 2 groups.

The mean age was 31.60 (range: 23-49) years in routine septoplasty group and 31 (range: 20-46) years in septoplasty with graft group.

According to VAS scale there was no difference in nasal breathing satisfaction between 2 groups before surgery (6.95 vs. 7.05,  $P = .23$ ), but significant improvement happened in septoplasty with graft group in comparison with routine septoplasty group 6 months after surgery (2.65 vs. 1.5,  $P < .001$ ) (Table 2).

The mean NOSE score was 57.75 in group 1 and 59 in group 2 before surgery with no significant difference ( $P = .597$ ), but statistically significant improvement occurred 6 months after surgery in group 2 (22.5 vs. 14.5,  $P < .001$ ) (Table 1).

## DISCUSSION

The concept of septoplasty first was popularized by Killian (1904) and Freer (1902) separately more than 100 years ago.<sup>19</sup>

Various techniques have been proposed for correction of deviated nasal septum. At first, submucous resection of septum was done as a radical surgery with a lot of complications. Later minimal resection recommended with less complications.<sup>8</sup>

In basic septoplasty a part of quadrangular cartilage is extracted for correcting the septal deviation and discarded.<sup>2,12</sup>

For enough nasal tip support, strong materials such as septal, auricular or rib graft or even implants are required and restoring cartilage from distant sources from nose may be difficult with specific complications. Septal cartilage is usually the best material for nose surgeries but it may be insufficient or missing during previous surgeries.<sup>14,20</sup>

**Table 2. Comparison of VAS and NOSE Between 2 Groups Before and 6 Months After Surgery**

	Group 1 N=20	Group 2 N=20	P
VAS scale (before)	6.95	7.05	.230
NOSE score (before)	57.75	59	.597
VAS scale (after)	2.65	1.50	<.001
NOSE score (after)	22.50	14.50	<.001

Therefore preserved septal cartilage can be very useful.

Guyuran et al<sup>21</sup> recommended cartilage removed during nasal surgery, specially septoplasty, is valuable and should be preserved for possible next use and this limits the need for harvesting a graft from other parts of body.

in a study Ghorbani et al<sup>22</sup> used transcutaneous columellar strut graft in septoplasty and showed that NOSE score was improved in all patients and also reinforced tip support and prevent from tip ptosis. Atighechi et al<sup>23</sup> used columellar strut with plumping graft in rhinoplasty for tip correction in patients with tip ptosis and found better breathing status.

Bloom et al<sup>24</sup> reported transcolumellar insertion of cartilage for further tip support in septoplasty and rhinoplasty cases. Also, in patients who need revision nose surgeries with fibrotic and scar tissue, graft insertion for tip or strut for columella can perform via transcolumellar approach.<sup>25</sup>

In a cohort study Novoa et al<sup>14</sup> found improvement in nasal breathing in 86% of septorhinoplasty cases after restoration of nasal tip support with autologous cartilaginous intercrural columellar strut graft.

In another study Sersar et al<sup>26</sup> used autologous diced rib cartilages in septoplasty and reported significantly nasal breathing improvement in 21 from 22 patients.

According to Stewart et al<sup>8</sup> and Shukla et al<sup>27</sup> studies, NOSE score was used for subjective assessment of patients satisfaction from septoplasty.

In this study we put the extracted part of quadrangular cartilage as a columellar strut graft between medial cruras in order to preserve better tip support, better nasal breathing and prevention from columellar tilting during deep breathing.

In this method we got maximum progression in nasal passage with minimum changes in nasal shape and tip ptosis and airway collapse.

NOSE and VAS have suitable framework for assessing the results of treatment.<sup>27</sup> We used from this 2-scaling system and found meaningful improvement in patient satisfaction after septoplasty with columellar strut graft; therefore, it can be recommended in septoplasties. There are some limitations in our study and in order to eliminate them, performing study with larger sample size and adding the result of rotation and projection after surgeries and compare them, and using from rhinomanometry, as an objective method recommended.

Using cartilaginous columellar strut graft in septoplasty is effective in improving nasal breathing satisfaction in patients after septoplasty. Therefore, it should be recommended in septoplasties.

**Ethics Committee Approval:** This study was approved by Ethics Committee of Shahed University (approval number: IR.SHAHED.REC.1 398.091.; date: 2018.11.23).

**Informed Consent:** Written informed consent was obtained from the patients who agreed to take part in the study.

**Peer-review:** Externally peer-reviewed.

**Author Contributions:** Concept – M.Y., P.I.; Design – B.M., M.Y, P.I.; Supervision – M.Y., P.I.; Resources – B.M., M.Y., P.I.; Materials – B.M., M.Y., P.I.; Data Collection and/or Processing – B.M., M.Y., P.I.; Analysis and/or Interpretation – B.M., M.Y., P.I.; Literature Search – B.M., M.Y., P.I.; Writing – B.M., M.Y., P.I.; Critical Review – B.M., M.Y., P.I.

**Declaration of Interests:** The authors have no conflict of interest to declare.

**Funding:** The authors declared that this study has received no financial support.

## REFERENCES

1. Kayabasi S, Cayir S, Hizli O. The effects of intraday operation time on pain and anxiety of patients undergoing septoplasty. *Braz J Otorhinolaryngol.* 2019;694(19):119-125.
2. Most SP, Rudy SF. Septoplasty: basic and advanced techniques. *Facial Plast Surg Clin North Am.* 2017;25(2):161-169. [CrossRef]
3. Hytönen ML, Lilja M, Mäkitie AA, Sintonen H, Roine RP. Does septoplasty enhance the quality of life in patients? *Eur Arch Otorhinolaryngol.* 2012;269(12):2497-2503. [CrossRef]
4. Akerlund A, Millqvist E, Oberg D, Bende M. Prevalence of upper and lower airway symptoms: the Skovde population based study. *Acta Otolaryngol.* 2006;126(5):483-488. [CrossRef]
5. Nurse LA, Duncavage JA. Surgery of the inferior and middle turbinates. *Otolaryngol Clin N Am.* 2009;42(2):295-309. [CrossRef]
6. Flint P, Haughey B, Lund V. *Cummings Otolaryngology Head and Neck Surgery.* 6th ed. Philadelphia: Saunders, 2015:477.
7. Hsia JC, Camacho M, Capasso R. Snoring exclusively during nasal breathing: a newly described respiratory pattern during sleep. *Sleep Breath.* 2014;18(1):159-164. [CrossRef]
8. Stewart MG, Smith TL, Weaver EM, et al. Outcomes after nasal septoplasty: results from the nasal obstruction septoplasty effectiveness (NOSE) study. *Otolaryngol Head Neck Surg.* 2004;130(3):283-290. [CrossRef]
9. Bezerra TFP, Stewart MG, Fornazieri MA, et al. Quality of life assessment septoplasty in patient with nasal obstruction. *Braz J Otorhinolaryngol.* 2012;78(3):57-62. [CrossRef]
10. Haroon Y, Saleh HA, Abou-Issa AH. Nasal soft tissue obstruction improvement after septoplasty without turbinectomy. *Eur Arch Otorhinolaryngol.* 2013;270(10):2649-2655. [CrossRef]
11. Duarte AF, Soler C, Zavarezzi F. Nasal endoscopy associated with paranasal sinus computerized tomography scan in the diagnosis of chronic nasal obstruction. *Braz J Otorhinolaryngol.* 2005;71(3):361-363. [CrossRef]
12. Giacomini PG, Mocella S, Di Girolamo S, De Berardinis R, Bocchieri A. The hump columellar strut: a reliable technique for correction of nasal tip underprojection. *Acta Otorhinolaryngol Ital.* 2018;38(1):45-50. [CrossRef]
13. Kuduban O, Bingol F, Budak A, Kucur C. The reason of dissatisfaction of patient after septoplasty. *Eurasian J Med.* 2015;47(3):190-193. [CrossRef]
14. Novoa E, Simmen D, Briner HR, Schlegel C. Long-term results after restoring nasal tip support using auricular cartilage as an intercrural columellar strut graft: the "I-Beam" technique. *Rhinology.* 2018;56(2):183-188. [CrossRef]
15. Flynn D, Van Schaik P, Van Wersch A. A comparison of multi-item Likert and Visual Analogue Scales for the assessment of transactionally defined coping function. *Eur J Psychol Assess.* 2004;20(1):49-58. [CrossRef]
16. Stewart MG, Witsell DL, Smith TL, Weaver EM, Yueh B, Hannley MT. Development and validation of the nasal obstruction symptom evaluation (NOSE) scale. *Otolaryngol Head Neck Surg.* 2004;130(2):157-163. [CrossRef]
17. Standlee AG, Hohman MH. Evaluating the effect of spreader grafting on nasal obstruction using the nose scale. *Ann Otol Rhinol Laryngol.* 2017;126(3):219-223. [CrossRef]
18. Garcia LBS, Oliveira PW, Vidigal TA, Suguri VM, Santos RP, Gregório LC. Caudal septoplasty: efficacy of a surgical technique-preliminary report. *Braslian J Orl.* 2011;77(2):178-184.
19. Dell'Aversana Orabona G, Romano A, Abbate V, et al. Effectiveness of endoscopic septoplasty in different types of nasal septal deformities: our experience with NOSE evaluation. *Acta Otorhinolaryngol Ital.* 2018;38(4):323-330. [CrossRef]
20. Duron JB, Aiach G. Cartilaginous graft in rhinoplasty. *Ann Chir Plast Esthet.* 2014;59(6):447-460. [CrossRef]
21. Guyuron B, Friedman A. The role of preserved autogenous cartilage graft in septorhinoplasty. *Ann Plast Surg.* 1994;32(3):255-260. [CrossRef]
22. Ghorbani J, Ganjali M, Givehchi G, Zangi M. Transcutaneous Columellar Strut for Correcting Caudal Nasal Septal Deviation. *Indian J Otolaryngol Head Neck Surg.* 2018;70(3):346-350.
23. Atighechi S, Sajadinejad BS, Baradaranfar MH, Dadgarnia MH, Shahbazian H. Caudal extension graft versus columellar strut with plumping graft for acute nasolabial angle correction in rhinoplasty surgery. *Eur Arch Otorhinolaryngol.* 2015;272(7):1673-1677.
24. Bloom DC, Cupp CL. The percutaneous columellar strut. *Am J Rhinol.* 2003; 17:357-361.
25. Aiach GC, Gerbault OF, Kelly MH. Secondary rhinoplasty. In: Nahai F (ed) *The art of aesthetic surgery principles and techniques*, 2nd edn. (2011) Quality Medical Publishing, ST. Louis, pp 2024-2100.
26. Sersar SI, Yassin I, Eldin AMS. Autologous Diced Cartilage in Nasal Septoplasty. *World J Plast Surg.* 2016;5(3):293-297.
27. Shukla RH, Nemade SV, Shinde KJ. Comparison of visual analogue scale (VAS) and the Nasal Obstruction Symptom Evaluation (NOSE) score in evaluation of post septoplasty patients. *World J Otorhinolaryngol Head Neck Surg.* 2020;6(1):53-58.